

Paravertebral Blocks: The Evolution of a Standard of Care

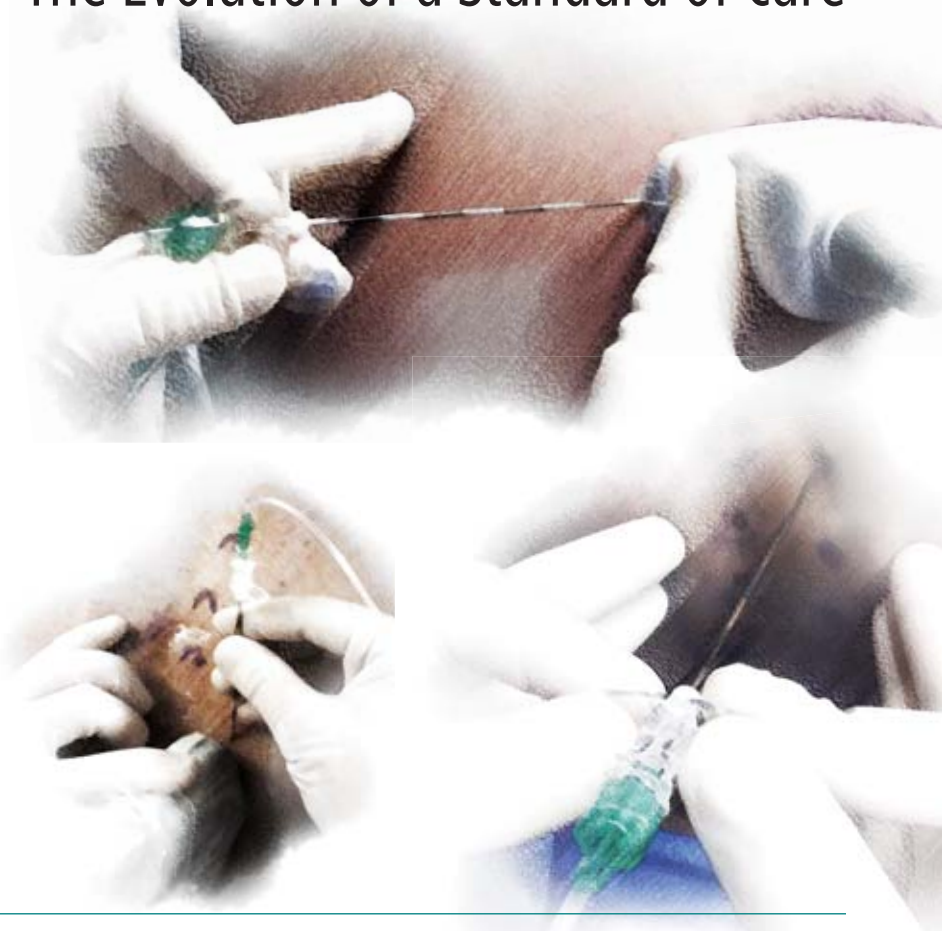KEVIN KING, DO

*Clinical Assistant Professor
Department of Anesthesiology
University of Pittsburgh Medical Center
Pittsburgh, Pennsylvania*

JACQUES E. CHELLE, MD, PhD, MBA

*Professor of Anesthesiology (with Tenure)
and Orthopedic Surgery
Vice Chair of Clinical Research
Director of the Regional and
Orthopedic Fellowships
Director of the Division of Acute Interventional
Perioperative Pain and Regional Anesthesia
Department of Anesthesiology
University of Pittsburgh Medical Center
Pittsburgh, Pennsylvania*

The authors have no relevant financial conflicts to disclose.



In 1905, Sellheim of Leipzig, Germany, first described a method to block nerves lateral to the spinal column as an alternative to central neuraxial blocks. This paravertebral approach was found to be safer than spinal anesthesia in the context of the limited monitoring and resuscitating capacity that characterized the era. Yet 30 years later, the technique was hardly mentioned in the literature and rarely practiced. Not until the late 1970s, when Eason and Watson reintroduced it, did the paravertebral approach gain widespread use.¹

Since that time, the technique has experienced extraordinary growth. As was the case initially, it is considered to be safer than neuraxial blocks—and particularly the thoracic epidural—for perioperative analgesia. The importance of this comparison is highlighted by the increased number of surgical and trauma patients who receive enoxaparin for thromboprophylaxis, a clear contraindication for the use of an epidural.

At the University of Pittsburgh Medical Center (UPMC), the paravertebral technique was introduced in 2003 as a single block for the perioperative management of patients undergoing open radical prostatectomy. This method was soon followed by the use of continuous paravertebral blocks (CPVBs) for the perioperative management of pain in patients undergoing thoracic surgery. Between July 1, 2010 and June 30,

2011, a total of 8,637 paravertebral blocks (PVBs) were performed, including the placement of 6,747 continuous paravertebral catheters.

Anatomy

Perhaps the most useful confirmation of the boundaries and contents of the paravertebral space (PVS) was performed by Klein et al on an unembalmed cadaver with an ankle endoscope.² They confirmed PVS is well defined by anatomic structures that were previously reported by Eason and Wyatt. Klein et al reported that the neural structures are simply surrounded by loose areolar or adipose tissue within the space.²

The wedge-shaped thoracic PVS can be distended by percutaneous introduction of medication for therapeutic purposes. The boundaries of the 3-sided wedge—posterior, medial boundary, and anterolateral—extend caudally and cephalad, as the segmental spaces communicate up and down. The PVS is bounded posteriorly by transverse processes, the rib heads, and the ligaments that travel between the adjacent transverse processes and ribs. The medial boundary is the vertebral body, the intervertebral disks, and the intervertebral foramen at each level. The anterolateral boundary

is the parietal pleura. Laterally, the space tapers as it communicates with the intercostal space. The thoracic PVS is the only location outside of the neuraxial column in which injected local anesthetic can block the ventral and dorsal rami, and the gray and white rami communicantes that carry the sympathetic fibers. The PVS extends from the cervical to the sacral spine.

The PVS is subdivided into an anterior (extrapleural) and a posterior (subendothoracic) space by the endothoracic fascia, which is continuous with the internal intercostal membrane laterally and the prevertebral fascia medially. Karmakar presented the first known radiologic evidence of a PVB spreading contralaterally by a nonepidural route following the injection of a large volume of local anesthetic solution.³ The local anesthetic and radiologic dye had spread anterior to the vertebral bodies.

Indications

Single PVBs have been used primarily for patients undergoing breast surgery with and without axillary dissection,⁴⁻⁷ inguinal and umbilical hernia repair,^{8,9} and thoracotomy and video-assisted thoracic surgery (VATS; Table). Although the technique has been shown to be effective in this indication, Hill et al demonstrated that for VATS, single PVBs do not provide analgesia beyond 8 hours postoperatively.¹⁰ Therefore, a CPVB is preferred in this indication¹¹⁻¹³ because it provides longer-lasting analgesia and shorter hospital length of stay (LOS).¹⁴ For breast surgery, the blocks are performed between T2 and T6, and a continuous technique is indicated for surgery including breast reconstruction. It is important to recognize that, based on a retrospective analysis, evidence supports the concept that the use of PVBs delays recurrence and the development of metastases.¹⁵

Multiple studies have shown that for patients undergoing axillary dissection during breast surgery, PVBs provide improved postoperative analgesia, and reduced incidence of nausea and vomiting, compared with general anesthesia alone, and shorter LOS.^{16,17} At UPMC, unilateral CPVB is used at T4-T5 for thoracotomy, as well as VATS and esophageal surgery. This technique also has been recommended for postoperative pain management following cardiac surgery.^{18,19}

Mid-thoracic-level CPVB is used for major abdominal cases²⁰⁻²² such as chemoperfusion, partial hepatectomy, nephrectomy, and colectomy, as well as for the occasional open repair of an abdominal aortic aneurysm.

For trauma and rib fracture cases, CPVBs are placed at the corresponding level of the injury. In this indication, it is not unusual to place 2 paravertebral catheters in the case of extended rib fractures.

Lower thoracic single-shot PVBs are routinely performed bilaterally at T10, T11, and T12 for radical prostatectomy due to the visceral input. Studies performed at UPMC have shown great efficacy with lower pain scores.²³ The same levels are blocked for laparoscopic

Table. Indications for Paravertebral Blocks

Single Level	Unilateral	
	Breast surgery	T1-T6
	Inguinal hernia	T10-L1
Continuous Level	Bilateral	
	Prostatectomy, hysterectomy	T10-L1
	Small umbilical hernia	T7-T10
	Unilateral	
	Breast surgery with node dissection	T2-T3
Continuous Level	Nephrectomy (lateral approach)	T6-T7
	Thoracotomy, VATS	T4-T5
	Bilateral	
	Major abdominal surgery (liver resection, midline approach for a nephrectomy, Whipple, pancreatectomy, small bile resection, etc)	T7-T8
	AAA	T7-T8
	Pelvic surgery (cystectomy, hysterectomy with node dissection)	T10-T11

AAA, abdominal aortic aneurysm; VATS, video-assisted thoracic surgery

abdominal hysterectomy. They even have been used for more minor abdominal surgeries such as umbilical hernia repair. These blocks are not routinely performed for laparoscopic cholecystectomy, although they provide excellent postoperative analgesia.²⁴

Pediatric anesthesiologists or anesthesiologists with advanced training in pediatric regional anesthesia can place pediatric PVBs.²⁵ PVBs also have been recommended for labor analgesia^{26,27} and the treatment of chronic pain syndromes.²⁸

The use of CPVBs also has been advocated for multiple rib fractures.²⁹ At UPMC, CPVBs have become the standard of care for the management of pain associated with multiple rib fractures, for several reasons:

1. Regional anesthesia has been shown to decrease morbidity and mortality in patients with multiple rib fractures.
2. Most patients received thromboprophylaxis with enoxaparin and the use of enoxaparin is a contraindication of epidurals.
3. PVBs have been shown to be equally effective as epidural analgesia.^{17,30-34}
4. The use of CPVBs for the management of pain following multiple rib fractures has been shown to be effective and safe in patients receiving enoxaparin for thromboprophylaxis.

The thoracic PVB is indicated for analgesia after thoracic, abdominal, or pelvic surgery when patients do not have an absolute contraindication—such as refusal, infection at the intended procedure site, or pharmacologic or uncontrolled anticoagulated states.

Of particular concern for many clinicians is the patient who presents for surgery prior to a 24-hour waiting period after having received therapeutic anticoagulation for the treatment of known venous thrombosis or pulmonary embolus. (Such a regimen might include enoxaparin 1 mg/kg subcutaneously twice daily; fondaparinux [Arixtra, GlaxoSmithKline] 7.5 mg subcutaneously once daily, and noninterrupted heparin infusion with prothrombin time 2 to 3 times the normal rate.)

In its Third Evidence-Based Guidelines, the American Society of Regional Anesthesia and Pain Medicine advises against the use of deep and plexus blocks in patients receiving antithrombotic or thrombolytic therapy.³⁵ These recommendations are based on very few case reports.

For the past 10 years, clinicians at UPMC have performed peripheral nerve blocks and PVBs in patients receiving thromboprophylaxis for deep vein thrombosis and pulmonary embolism either postoperatively or because of multiple rib fractures. The combination of CPVBs and thromboprophylaxis has not been associated with any significant bleeding, particularly at the time of the removal of the paravertebral catheter. At UPMC, administration of the thromboprophylaxis is not discontinued and these catheters are removed without consideration for the type of drug used for thromboprophylaxis or the timing of administration.³⁶⁻³⁹

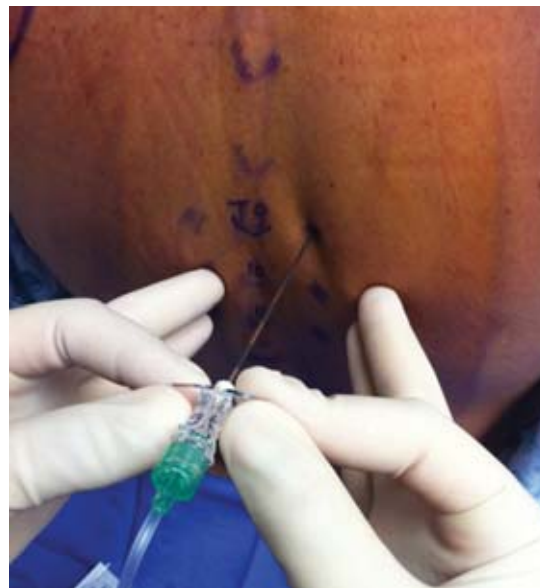

Figure 1. Classic approach for single blocks.

The needle is introduced 2.5 cm lateral from the spinous process in search of the transverse process.

Techniques

PATIENT POSITIONING

Most PVBs are best performed in the sitting position. However, in patients lacking mobility—because they are intubated, for example, or have experienced trauma—PVBs can be performed in the lateral position. Although it is possible to perform PVBs when the patient is prone, it is important to recognize that this position increases the time required to perform the block.

LOCALIZATION OF THE THORACIC LEVEL

Regardless of the technique, it is necessary to first determine the level at which the PVB should be performed. Several approaches are available:

1. Use the C7 spinous process (vertebra prominens) as the initial point to count down spinous processes.
2. Start at the edge of the scapular, which enables the localization of the space between T7 and T8 within ± 1 level. (Technique 1 has been shown to be more accurate than this technique).⁴⁰
3. Localize the 12th rib and count the ribs upward, using either surface landmarks or ultrasound.

BLIND TECHNIQUES

Several techniques are described based on the use of surface landmarks not requiring the use of ultrasound: classic, neurostimulation, loss of resistance, and intercostal.

Classic (Figure 1). The needle (22-gauge Tuohy for single PVBs and an 18-gauge Tuohy for CPVBs) is introduced 2.5 cm lateral from the top of the desired

vertebral body in search of the transverse process. Once contact is made with the transverse process, the needle is withdrawn to the skin and is redirected caudally 1 cm below the transverse process. The depth of the PVS varies according to the thoracic level.⁴¹ Frequently, the correct positioning of the needle is associated with a loss of resistance as the needle travels through the costal ligament. Next, 5 mL of local anesthetic solution is slowly injected per level (single PVBs) or before the introduction of the catheter, which is positioned 3 to 5 cm beyond the tip of the needle in the case of CPVB. The Tuohy introducer needle is removed and the catheter is secured in place with Steri-strips (3M) and covered with a transparent dressing.

Neurostimulation. Using the same landmark as the classic approach, a 10-cm 18-gauge insulated Tuohy is connected to a nerve stimulator set up to deliver 1.5 mA, 0.1 milliseconds at a frequency of 2 Hz. The positioning

of the needle produces an ipsilateral contraction of the corresponding intercostal muscles.^{42,43}

Loss of Resistance. Using the same landmark as the classic approach, an 18-gauge Tuohy needle is connected to tubing, which is also connected to a pressure transducer filled with saline. A sudden drop in pressure characterizes the introduction of the needle in the PVS.⁴⁴

Intercostal. In this approach, an 18-gauge Tuohy needle is introduced between 2 ribs corresponding to the desired paravertebral level 8 cm from the corresponding spinous process. After the rib is contacted, the needle is oriented at a 60-degree angle and introduced medially for another 2 cm with the bevel oriented medially. Three milliliters of local anesthetic is injected slowly after negative aspiration for blood before the introduction of the catheter. The catheter is introduced 6 cm beyond the tip of the needle.⁴⁵

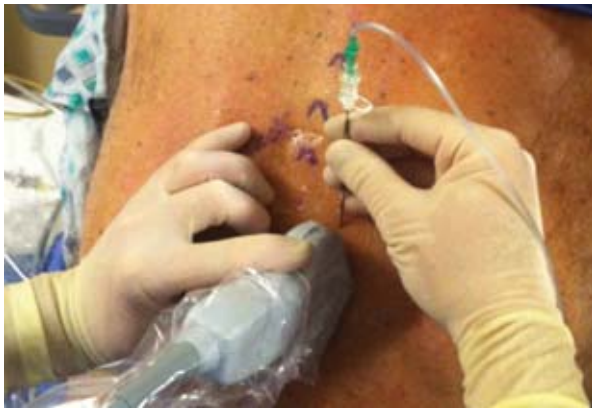

Figure 2a. Ultrasound-guided classic approach.

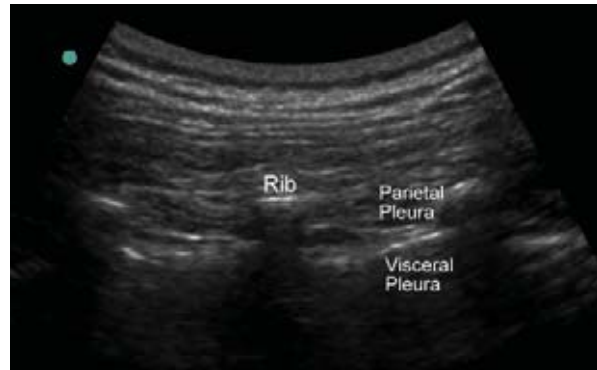

Figure 3. When the transducer is too lateral, the paravertebral space appears narrower.

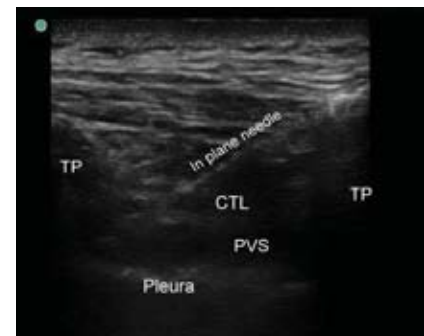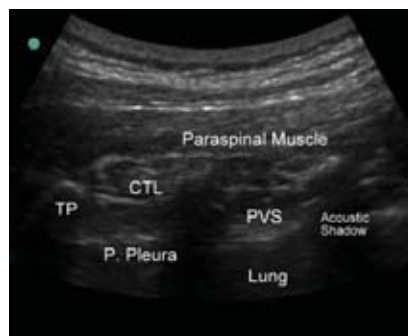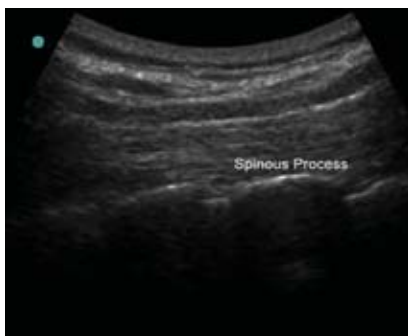


Figure 2b. Ultrasound-guided classic approach.

Left: The ultrasound transducer is positioned longitudinally at the level of the spinous process.

Center: The transducer is moved laterally in search of the transverse processes.

Right: The injection of the local anesthetic solution pushes the pleura anteriorly and disperses over several thoracic levels.

ULTRASOUND-GUIDED THORACIC PARAVERTEBRAL BLOCK

There are at least 3 described approaches to performing an ultrasound-guided PVB: The classic approach, in which the probe is positioned parallel to the spinal processes⁴⁶; an intercostal approach, which is used only for the placement of a paravertebral catheter⁴⁷; and a proximal lateral approach, in which the probe is placed perpendicular to the spinous processes.

Classic. After identifying the proper thoracic level, the curved low-frequency probe is placed longitudinally parallel and medially in search of spinous processes.⁴⁸ These will appear as bright white lines in a wave or sawtooth pattern. Next the probe is translated laterally in search of the transverse processes. Between the bright, hyperechoic cortices of the transverse processes and the underlying acoustic shadows is a less echogenic line connecting the bone that represents the costovertebral ligaments (CTL). Typically, the PVS is confirmed by viewing the CTL and an underlying echogenic line that represents the proximal and distal pleura. The PVS is between the CTL and the line of the pleura (Figures 2a and 2b). The PVS may have less anterior-posterior dimension if the probe is placed too far lateral of the spinous processes (Figure 3).

The needle is advanced in-plane and medially. A distinctive loss of resistance is felt when the needle passes through the CTL. After proper placement of the needle, local anesthetics may be injected. The injection may

result in an isolated push anteriorly of the pleura, or better, a distribution of the anesthetic solution throughout multiple levels, but with a less evident push of the pleura. Multilevel distribution confirms that the needle is indeed in the PVS. Our institution and others have reported that the spread resulting from a single injection of 10 to 15 mL of local anesthetic with dye can take several shapes and can extend up to 6 or 7 dermatomes.

Intercostal. The ultrasound transducer is positioned between the ribs of the desired level at a distance of 8 cm from the spinous process. The needle is placed in-plane and medially, between the internal and innermost intercostal muscles. Two to 3 mL of local anesthetic should be injected prior to placing the catheter, which should extend 8 cm beyond the tip of the needle (Figure 4).⁴⁷

PROXIMAL LATERAL APPROACH

The probe is placed perpendicular to the longitudinal plane of the spinous processes (Figure 5). The needle is introduced in-plane in a medial direction. This approach

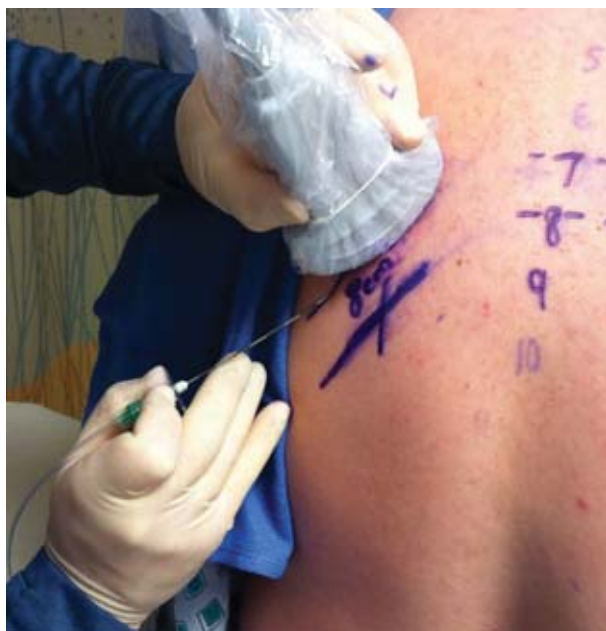

Figure 4. Intercostal approach to the paravertebral space. The line indicates the space between ribs 6 and 7.

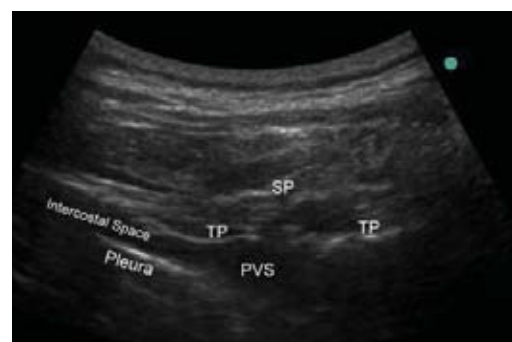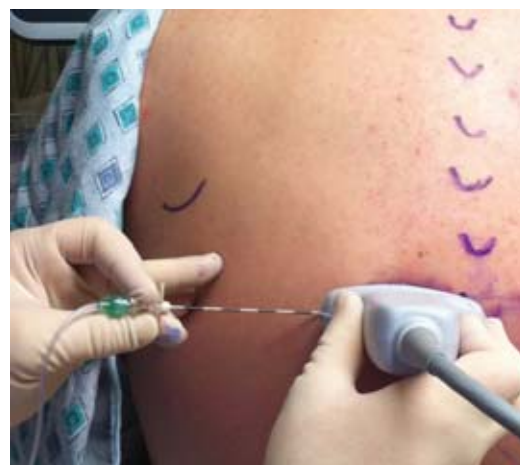


Figure 5. Proximal lateral approach with horizontally oriented probe and needle position (top), with corresponding sonoanatomy (bottom).

has been reported to be associated with 30% to 70% epidural spread and with the frequent placement of the catheter in the epidural space.⁴⁸ Therefore, this is not a recommended approach. Furthermore, Luyet reported that the use of this technique is associated with a failure rate of up to 45% when inserted 5 cm beyond the needle, as the catheters became lodged into the epidural space and dislodged into paraspinal muscle.

Regardless of the technique, once the needle is in the paravertebral space, 5 mL of ropivacaine 0.5% is injected slowly after negative aspiration for blood. If a single PVB is performed, this process is repeated at another level. Naja et al demonstrated that the spread of local anesthetic was greater when using a multilevel injection than with a single injection,⁴² without any effects on the local anesthetic absorption.⁴⁹ If a CPVB is performed, the catheter is introduced after the initial injection. When the catheter is secured in place, another 10 mL of ropivacaine 0.5% is injected slowly after negative aspiration for blood, for a total of 15 mL per catheter.

The paravertebral catheter is infused with either bupivacaine 0.0625% or lidocaine 0.25% at a starting rate of 7 mL per hour. The rate can be increased to 10 mL per hour if necessary. Orders should also include a bolus of 3 mL per hour, as needed, given by the nurse. The advantage of lidocaine is that it is safer, and when in doubt, determining the plasma level of the drug is simple. Ropivacaine 0.2% also has been reported as an alternative for continuous infusion. Regardless of the solution, the total rate should not exceed 20 mL per hour.

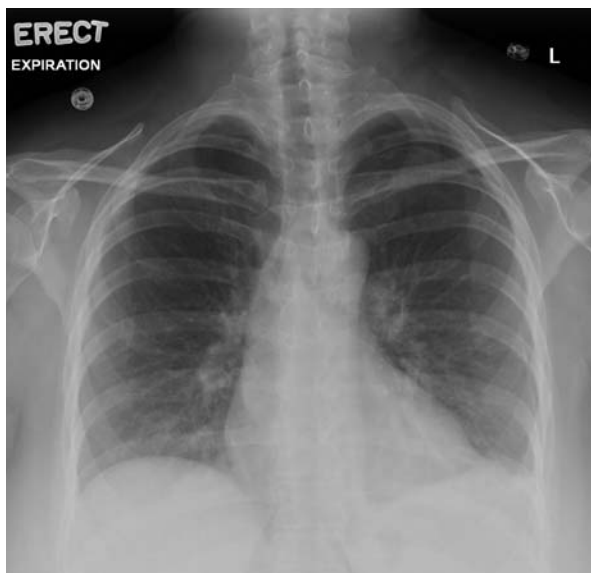

Figure 6. Chest x-ray illustrates 15% pneumothorax following continuous paravertebral block. No chest tube was placed.

Complications

Complications of PVBs are rare. The most frequent is the development of vagal episodes during the performance of the block, and serious adverse events include development of a pneumothorax, major bleeding, infection, epidural or intrathecal spread, headache, and local anesthetic toxicity.⁵⁰⁻⁵³ Hypotension also may occur; however, it is less frequent than has been associated with thoracic epidurals. In this regard, the use of ultrasound to guide the blocks may help avoid the complications related to an incorrect placement of the needle or catheter, such as pneumothorax, epidural injection, and the placement of an epidural catheter.

Pneumothorax is considered a classic complication of PVB, and is estimated to occur in between 0.5% and 1% of patients undergoing blocks (Figure 6). Yet it often is difficult to establish that the block caused the pneumothorax, particularly in patients undergoing major abdominal or pelvic surgeries or those in whom a central line has been placed. Clinicians must be vigilant for this event. Performing a PVB under direct vision at least theoretically reduces the risk for placing the needle beyond the pleura, as long as the clinician maintains good visualization of the needle. Visualization of the needle during the performance of a PVB is among the most challenging aspects of the procedure because the needle often is introduced at a steep angle. Use of echogenic needles or software that enhance the quality of the image can facilitate visualization of the needle and should be considered.

At UPMC, we have observed 3 pneumothoraces requiring the placement of a chest tube. In every case, the PVBs were not performed with the use of ultrasound. Although it is important to recognize that the use of ultrasound would most likely not completely eliminate this complication, performing these blocks under direct visualization can certainly help reduce the frequency of this complication.

CONTINUOUS PARAVERTEBRAL OR THORACIC EPIDURAL: NOT JUST A MATTER OF PREFERENCE

Many clinicians consider their choice of method to be a matter of personal preference. However, the data suggest otherwise.

It is well established that the placement of a thoracic epidural is difficult and associated with frequent failure. In contrast, the success rate associated with PVBs is high. As discussed earlier, the use of an epidural is contraindicated in patients receiving thromboprophylaxis initiated postoperatively. We have placed paravertebral catheters in patients undergoing major surgery or with multiple rib fractures in whom thromboprophylaxis was initiated after the procedure. In these patients, the catheters were removed without interruption and timing of the anticoagulation administration. Using such an approach, we did not observe any significant bleeding. The same is true for patients who have transient coagulopathy, such as those undergoing liver resection. However, the risk for epidural hematoma in patients taking

Steps To Minimize Complications and Failed Blocks

1. Use ultrasound guidance whenever possible.
2. Perform a full assessment of each patient prior to the procedure. The basic medical history can help avoid the performance of deep blocks on patients who are actively anticoagulated.
3. Be prepared to treat side effects and complications: vagal response during the performance of the block (5%-10% of symptoms include bradycardia and hypotension, possibly preceded or accompanied by lightheadedness, diaphoresis, and nausea. Approximately 50% of these patients require more than simply a change of posture. IV fluid boluses, IV glycopyrolate or atropine, ephedrine, or even epinephrine may be indicated), changes associated with an epidural and intrathecal administration of local anesthetics.
4. Use in-plane needle advancement. Do not advance unless the tip is visible.
5. When advancing the needle, keep a closed system with fluid-filled tubing connected to the Tuohy needle. Doing so confers some safety and prevents a parietal pleural puncture from converting to a pneumothorax.
6. Avoid the temptation to push the paravertebral catheter too far. No more than 4 to 5 cm should be inserted beyond the tip of the needle.

low-molecular-weight heparin who receive an epidural catheter is well established. Indeed, in these patients, use of an epidural is contraindicated. The relative safety of PVBs in anticoagulated patients is particularly important, considering that regional anesthesia and analgesia reduce overall morbidity and mortality in this patient population.

Continuous PVBs are less likely to cause hypotension associated with sympathetic blockade, particularly when placed unilaterally. Because the local anesthetic solutions for PVBs do not include opioids, patients benefiting from these techniques are less likely to experience pruritus or urinary retention. As a result, placement of a PVB does not necessitate the use of a Foley catheter, thus reducing the patient's risk for urinary tract infections, which are associated with these devices.

PVBs are associated with fewer side effects, consume fewer nursing resources, and require less monitoring than do thoracic epidurals.⁵⁴ In many institutions, patients who receive thoracic epidurals must be admitted to the intensive care unit, which is not necessary with PVBs.

In patients with multiple rib fractures and lumbar spine trauma, the use of continuous thoracic PVB for analgesia and preservation of respiratory function does not interfere with neurologic assessment for signs of spinal cord compression. Although this may not be a common occurrence, it displays the versatility and efficacy of CPVBs.

The Case for Thoracic Epidurals

Despite the advantages of PVBs, thoracic epidural analgesia is not without its advocates. In a recent review, Norum and Brevik argued that optimally conducted epidural analgesia has not been compared with PVBs, and that most studies of the 2 techniques were seriously flawed because the thoracic catheters was placed several segments too low.⁵⁵ They also noted that only 1 of the 10 studies they reviewed used opioids and

adrenaline (epinephrine) in the thoracic epidural solution. Epidurals performed without an opioid and adrenaline (or α -2 agonist) lose efficacy and the increased volume to achieve analgesia causes dose-related adverse effects of local anesthetics including hypotension, lower extremity motor block, and urinary retention.

The authors also stated that the most sensitive outcome variable for post-thoracotomy pain relief is pain intensity on coughing (dynamic pain). However, many studies used depth of breathing. Although persuasive, the authors admit their personal bias against PVBs reflects a case of sudden and permanent paraplegia in a patient receiving the block, and they speculate that this complication resulted from disruption or injection into the radicular artery that supplied the lower spinal cord. This case has not been published. The authors state the available randomized controlled studies were not large enough to evaluate for the rare but serious or fatal events that can occur in patients receiving these blocks.

Conclusion

The indications for the safe use of PVBs have expanded in recent years, as more anesthesiologists become experienced with the technique. This procedure increasingly is recognized as an effective and safer alternative to the thoracic epidural in patients receiving thromboprophylaxis.

References

1. Eason MJ, Wyatt R. Paravertebral thoracic block—a reappraisal. *Anaesthesia*. 1979;34(7):638-642.
2. Klein SM, Nielsen KC, Ahmed N, Buckenmaier CC, Steele S. In situ images of the thoracic paravertebral space. *Reg Anesth Pain Med*. 2004;29(6):596-599.
3. Karmakar MK, Kwok WH, Kew J. Thoracic paravertebral block: radiological evidence of contralateral spread anterior to the vertebral bodies. *Br J Anaesth*. 2000;84(2):263-265.
4. Greengrass R, O'Brien F, Lyerly K, et al. Paravertebral block for breast cancer surgery. *Can J Anesth*. 1996;43(8):858-861.

5. Buckenmaier CC 3rd, Steele SM, Nielsen KC, Klein SM. Paravertebral somatic nerve blocks for breast surgery in a patient with hypertrophic obstructive cardiomyopathy. *Can J Anesth.* 2002;49(6):571-574.
6. McElroy S., Colaizzi I, Flemming T, Chelly JE. Continuous paravertebral nerve blocks for postoperative pain management after secondary breast reconstruction using tissue expanders. *Anesth Analg.* 2009;108:S324.
7. Moreno MG, McElroy S, Colaizzi I, Fleming T, Chelly JE. Continuous paravertebral nerve block for postoperative pain management after radical mastectomy with axillary node dissection (RMAND). *Anesth Analg.* 2009;108:S327.
8. Klein SM, Greengrass RA, Weltz C, Warner DS. Paravertebral somatic nerve block for outpatient inguinal herniorrhaphy: an expanded case report of 22 patients. *Reg Anesth Pain Med.* 1998; 23(3):306-310.
9. Hadzic A, Kerimoglu B, Loreio D, et al. Paravertebral blocks provide superior same-day recovery over general anesthesia for patients undergoing inguinal hernia repair. *Anesth Analg.* 2006;102(4):1076-1081.
10. Hill SE, Keller RA, Stafford-Smith M, Grichnik K, et al. Efficacy of single-dose, multilevel paravertebral nerve blockade for analgesia after thoracoscopic procedures. *Anesthesiology.* 2006;104(5):1047-1053.
11. Marret E, Bazelly B, Taylor G. Paravertebral block with ropivacaine 0.5% versus systemic analgesia for pain relief after thoracotomy. *Ann Thorac Surg.* 2005;79(6):2109-2113.
12. Català E, Casas JI, Unzueta MC, Diaz X, Aliaga L, Villar Landeira JM. Continuous infusion is superior to bolus doses with thoracic paravertebral blocks after thoracotomies. *J Cardiothorac Vasc Anesth.* 1996;10(5):586-588.
13. Ben-David B, Merman R, Chelly JE. Paravertebral blocks for thoracoscopy: single no, continuous yes. *Anesthesiology.* 2007; 106(2):398-399.
14. Chelly JE, Ben-David B, Rest C, Uskova A, Pizzi L. Continuous paravertebral blocks reduce the hospital length of stay following thoracotomy. ASA, CD 2005.
15. Exadaktylos AK, Buggy DJ, Moriarty DC, Mascha E, Sessler DI. Can anesthetic technique for primary breast cancer surgery affect recurrence or metastasis? *Anesthesiology.* 2006;105(4):660-664.
16. Naja MZ, Ziade MF, Lönnqvist PA. Nerve-stimulator guided paravertebral blockade vs. general anaesthesia for breast surgery: a prospective randomized trial. *Eur J Anaesthesiol.* 2003;20(11):897-903.
17. Davies RG, Myles PS, Graham JM. A comparison of the analgesic efficacy and side-effects of paravertebral vs. epidural blockade for thoracotomy—a systematic review and meta-analysis of randomized trials. *Br J Anaesth.* 2006;96(4):418-426.
18. Olivier JF, Bracco D, Nguyen P, Le N, Noiseux N, Hemmerling T; Perioperative Cardiac Surgery Research Group (PeriCARG). A novel approach for pain management in cardiac surgery via median sternotomy: bilateral single-shot paravertebral blocks. *Heart Surg Forum.* 2007;10(5):E357-E62.
19. Lee JK, Pearce-Smith B, Wei L, Chelly JE. Continuous paravertebral catheters in patients who underwent minimally invasive cardiac surgery: a case series. Presented at: American Society of Regional Anesthesia and Pain Medicine; May 5-8, 2011; Las Vegas, NV.
20. Culp WC Jr, Culp WC. Thoracic paravertebral block for percutaneous transhepatic biliary drainage. *J Vasc Interv Radiol.* 2005;16(10): 1397-1400.
21. Burns DA, Ben-David B, Chelly JE, Greensmith JE. Intercostally placed paravertebral catheterization: an alternative approach to continuous paravertebral blockade. *Anesth Analg.* 2008;107(1): 339-341.
22. Finnerty O, Carney J, McDonnell JG. Trunk blocks for abdominal surgery. *Anaesthesia.* 2010;65 (suppl 1):76-83.
23. Chelly JE, Ploskanych T, Dai F, Nelson JB. Multimodal analgesic approach incorporating paravertebral blocks for open radical retropubic prostatectomy: a randomized double-blind placebo-controlled study. *Can J Anesth.* 2011;58(4):371-378.
24. Naja ZM, El-Rajab M, Ziade F, Al-Tannir M, Itani T. Preoperative vs. postoperative bilateral paravertebral blocks for laparoscopic cholecystectomy: a prospective randomized clinical trial. *Pain Pract.* 2011;11(6):509-515.
25. Tsai T, Rodriguez-Diaz C, Deschner B, Thomas K, Wasnick JD. Thoracic paravertebral block for implantable cardioverter-defibrillator and laser lead extraction. *J Clin Anesth.* 2008;20(5):379-382.
26. Suelto MD. Paravertebral lumbar sympathetic block for labor analgesia. *Anesthesiology.* 2000;93(2):580.
27. Choi S, Brull R. Neuraxial techniques in obstetric and non-obstetric patients with common bleeding diatheses. *Anesth Analg.* 2009; 109(2):648-660.
28. Chaturvedi A, Dash HH. Sympathetic blockade for the relief of chronic pain. *J Indian Med Assoc.* 2001;99(12):698-703.
29. Karmakar MK, Chui PT, Joynt GM, Ho AM. Thoracic paravertebral block for management of pain associated with multiple fractured ribs in patients with concomitant lumbar spinal trauma. *Reg Anesth Pain Med.* 2001;26(2):169-173.
30. Richardson J, Sabanathan S, Jones J, Shah RD, Cheema S, Mearns AJ. A prospective, randomized comparison of preoperative and continuous balanced epidural or paravertebral bupivacaine on post-thoracotomy pain, pulmonary function and stress responses. *Br J Anaesth.* 1999;83(3):387-392.
31. Dhole S, Mehta Y, Saxena H, Juneja R, Trehan N. Comparison of continuous thoracic epidural and paravertebral blocks for postoperative analgesia after minimally invasive direct coronary artery bypass surgery. *J Cardiothorac Vasc Anesth.* 2001;15(3):288-292.
32. Casati A, Alessandrini P, Nuzzi M, Tosi M, et al. Prospective, randomized, blinded comparison between continuous thoracic paravertebral and epidural infusion of 0.2% ropivacaine after lung resection surgery. *Eur J Anaesthesiol.* 2006;23(12):999-1004.
33. Mohta M, Verma P, Saxena AK, Sethi AK, Tyagi A, Girotra G. Prospective, randomized comparison of continuous thoracic epidural and thoracic paravertebral infusion in patients with unilateral multiple fractured ribs—a pilot study. *J Trauma.* 2009;66(4):1096-1101.
34. Scarci M, Joshi A, Attia R. In patients undergoing thoracic surgery is paravertebral block as effective as epidural analgesia for pain management? *Interact Cardiovasc Thorac Surg.* 2010;10(1):92-96.
35. Horlocker TT, Wedel DJ, Rowlingson JC, et al. Regional anesthesia in the patient receiving antithrombotic or thrombolytic therapy: American Society of Regional Anesthesia and Pain Medicine Evidence-Based Guidelines (Third Edition). *Reg Anesth Pain Med.* 2010;35(1):64-101.
36. Gierl B, Alarcon L, Chelly JE. Safety associated with the removal of paravertebral catheters in trauma patients receiving enoxaparin for thromboprophylaxis. Presented at: American Society of Regional Anesthesia and Pain Medicine; May 5-8, 2011; Las Vegas, NV.
37. Conrad E, Chelly JE, Shick V, Mukalel J. Combination of enoxaparin and continuous paravertebral blocks for major gynecologic surgery. Presented at: American Society of Regional Anesthesia and Pain Medicine; May 5-8, 2011; Las Vegas, NV.
38. Gierl BT, Conrad E, Alarcon L, Chelly JE. Safety associated with the removal of paravertebral catheters in trauma patients receiving LMWH for thromboprophylaxis. Presented at: American Society of Anesthesiologists; October 15-19, 2011; Chicago, IL.
39. Chelly JE, Schilling D. Thromboprophylaxis and peripheral nerve blocks in patients undergoing joint arthroplasty. *J Arthroplasty.* 2008;23(3):350-354.
40. Teoh DA, Santosham KL, Lydell CC, Smith DF, Beriault MT. Surface anatomy as a guide to vertebral level for thoracic epidural placement. *Anesth Analg.* 2009;108(5):1705-1707.

41. Chelly JE, Uskova A, Merman R, Szczodry D. A multifactorial approach to the factors influencing determination of paravertebral depth. *Can J Anesth*. 2008;55(9):587-594.
42. Naja ZM, El-Rajab M, Al-Tannir MA, et al. Thoracic paravertebral block: influence of the number of injections. *Reg Anesth Pain Med*. 2006;31(3):196-201.
43. Boezaart A, Lucas SD, Elliott CE. Paravertebral block: cervical, thoracic, lumbar, and sacral. *Curr Opin Anaesthesiol*. 2009;22(5):637-643.
44. Richardson J, Cheema SP, Hawkins J, Sabanathan S. Thoracic paravertebral space location. A new method using pressure measurement. *Anaesthesia*. 1996;51(2):137-139.
45. Burns DA, Ben-David B, Chelly JE, Greensmith JE. Intercostally placed paravertebral catheterization: an alternative approach to continuous paravertebral blockade. *Anesth Analg*. 2008;107(1):339-341.
46. Montoya M, Fanelli A, Chelly JE. Frequent epidural spread can be prevented when performing an ultrasound guided approach to the paravertebral space. *Br J Anaesth* (e-Letter). June 16, 2009.
47. Ben-Ari A, Moreno M, Chelly JE, Bigeleisen PE. Ultrasound-guided paravertebral block using an intercostal approach. *Anesth Analg*. 2009;109(5):1691-1694.
48. Luyet C, Eichenberger U, Greif R, Vogt A, Szücs Farkas Z, Morigg B. Ultrasound-guided paravertebral puncture and placement of catheters in human cadavers: an imaging study. *Br J Anaesth*. 2009;102(4):534-539.
49. Lemay E, Guay J, Côté C, Boivin MC, Varin F. The number of injections does not influence local anesthetic absorption after paravertebral blockade. *Can J Anesth*. 2003;50(6):562-567.
50. Merman R, Burman K, Uskova A, Chelly JE. Hypotensive bradycardic events and paravertebral blocks in the sitting position. *Anesth Analg*. 2006;102:S-134.
51. Adelman H, Irwin I. Acute aseptic meningitis following paravertebral lumbar sympathetic blocks. *Anesthesiology*. 1946;7:422-425.
52. Lönnqvist PA, MacKenzie J, Soni AK, Conacher ID. Paravertebral blockade. Failure rate and complications. *Anaesthesia*. 1995;50(9):813-815.
53. Lin HM, Chelly JE. Post-dural headache associated with thoracic paravertebral blocks. *J Clin Anesth*. 2006;18(5):376-378.
54. Pintaric TS, Potocnik I, Hadzic A, Stupnik T, Pintaric M, Jankovic VN. Comparison of continuous thoracic epidural with paravertebral block on perioperative analgesia and hemodynamic stability in patients having open lung surgery. *Reg Anesth Pain Med*. 2011;36(3):256-260.
55. Norum HM, Breivik H. A systematic review of comparative studies indicates that paravertebral block is neither superior nor safer than epidural analgesia for pain after thoracotomy. *Scand J Pain*. 2010;1(1):12-23.