



# Provocative discography as predictor of discogenic pain and therapeutic outcome

Clarence S. Ivie, DO, Daniel Gianoli, MD, Carlos A. Pino, MD

*From the Department of Anesthesiology, University of Vermont College of Medicine, Burlington, Vermont.*

## KEYWORDS:

Discography;  
Lumbar;  
Back pain;  
Discogenic;  
Disk degeneration;  
IDET

The use of provocative discography (discography) in diagnosing degenerative disk disease and predicting surgical outcomes is a subject of ongoing debate. Magnetic resonance imaging and computed tomography are the preferred methods for visualizing disk morphology. While these advanced imaging studies produce a superior anatomical assessment and can identify surgically correctable lesions, discography is the only available method to determine whether an abnormally appearing disk is also painful. Discography is a subjective test, relying entirely on the patient's description of pain during the procedure. Therefore, controversies and concerns for its diagnostic accuracy and validity have been abundant since the technique was first described. Due to the perplexing problem of evaluating and treating chronic low back pain, discography is still considered by many to provide useful information in planning the surgical management of spinal pain from discogenic disease. This article presents a general overview of lumbar discography and the current state of evidence for its use in predicting treatment outcomes.

© 2011 Elsevier Inc. All rights reserved.

Low back pain (LBP) is a highly prevalent condition and major cause of suffering and impairment throughout the world, affecting individuals of all ages. Based on a recent review of epidemiologic data, the lifetime prevalence rate for LBP ranges from 51% to 84% among the general population, with 2% to 5% seeking medical attention for LBP annually.<sup>1,2</sup> Furthermore, findings from cross-sectional survey studies suggest that prevalence rates for LBP are increasing.<sup>1,3,4</sup> Most acute LBP cases will resolve after a benign self-limited course; however, approximately 20% will experience a recurrent episode within 6 months.<sup>5</sup> The percentage of patients who progress to chronic LBP has been estimated from 5% to 20%.<sup>6-10</sup>

Many patients with chronic LBP are able to manage their symptoms with standard conservative therapies. For pa-

tients who continue to experience severe pain and disability despite these measures, it may be appropriate to consider consultation with a spine specialist<sup>11</sup> for consideration of more advanced therapies. In these difficult cases, successful treatment is commonly thought to rely on identification of the primary pain-producing structure.<sup>12-14</sup> Many interventional therapies are directed toward specific pathology and should not be expected to produce significant improvement without an accurate diagnosis. The importance of establishing specific pain diagnosis is not without opposition.<sup>11,15</sup> Guidelines for the treatment of LBP from the American Pain Society point to a lack of evidence that using this approach improves outcomes.<sup>11</sup>

Identifying the specific pathology responsible for an individual patient's LBP can be particularly challenging. The presentation and symptomatology of LBP is often nonspecific, with many possible etiologies. Possible sources of chronic LBP include soft tissue structures (muscles, fascia, and ligaments of the lumbar spine), intervertebral disks, facet joints, and the sacroiliac joints.<sup>16-18</sup> Complicating the

---

**Address reprint requests and correspondence:** Clarence S. Ivie, DO, Center for Pain Medicine, Department of Anesthesiology, University of Vermont College of Medicine, 62 Tilley Drive, South Burlington, VT 05403.

E-mail address: [Clarence.ivie@vtmednet.org](mailto:Clarence.ivie@vtmednet.org).

matter further, axial LBP may be referred from sources outside of the spinal column.<sup>19,20</sup> Conventional imaging reveals a high prevalence of abnormal anatomic findings among asymptomatic populations, while patients with chronic LBP may appear normal.<sup>21-24</sup> In this article we present a general overview of discogenic LBP (DLBP), describe the diagnostic role of lumbar discography, and discuss the current state of evidence for its use in predicting therapeutic outcomes.

## Discogenic low back pain

DLBP, defined as pain arising from internal disk disruption, is now a commonly accepted clinical entity.<sup>25-27</sup> Our understanding of the pathophysiology involved in disk degeneration, as it relates to pain, has improved considerably over the last 3 decades. Several studies have produced convincing evidence to support the theory of intervertebral disks as a source of axial back pain.

Most importantly, studies have confirmed that disks are innervated and can be a source of pain.<sup>28,29</sup> In the normal lumbar intervertebral disk, sensory fibers extend into the outer third of the annulus.<sup>30</sup> Posteriorly, the disk is innervated by the sinuvertebral nerve, formed by a recurrent branch of the ventral ramus and a branch of the gray rami communicantes.<sup>31</sup> The ventral surface of the disk is innervated by a plexus formed by the sympathetic trunk, its rami communicantes, and perivascular nerves. Branches from the gray rami communicantes also supply the lateral surface of the annulus. Additionally, each lumbar sinuvertebral nerve sends branches superiorly and inferiorly, supplying the disk above and below, in addition to the disk at the level of origin of the nerve.<sup>32</sup> Degenerated disks exhibit abnormally widespread innervation with sensory nerve fibers penetrating deeper into the nucleus pulposus.<sup>32,33</sup>

In addition to understanding disk innervation, our knowledge of common pathologic findings observed in painful disks has grown in recent years. We know that most disks with positive pain provocation on discography will exhibit radial fissures within the annulus.<sup>34</sup> Histologic studies demonstrate ingrowth of vascularized granulation tissue along the annular fissures.<sup>35</sup> By studying the granulation tissue through immunohistochemical analyses, researchers have found cytokine-sensitized nociceptors, phagocytic cells, and perivascular neoinnervation. There may also be small free nerve fibers (axonogenesis), not only in the outer annulus, but also extending to the inner annulus and nucleus pulposus.<sup>33,36-39</sup>

It is also evident that the process of disk degeneration produces an inflammatory response, generated by cells within the nucleus pulposus, where a large number of inflammatory factors are released. Patients with DLBP have significantly higher levels of released interleukin-1 (IL-1), IL-6, and IL-8 compared to patients with disk herniation.<sup>37</sup> These inflammatory factors migrate through fissures into the

outer third of the annulus, or into the end plate, where stimulation of free nerve endings results in pain. Therefore, degenerative disks exhibit free nerve endings (pain receptors) and inflammation, 2 factors responsible for inducing pain.<sup>40</sup>

Despite a growing body of evidence, the existence of DLBP remains a topic of debate. Some investigators consider the concept of discogenic pain to be unfounded. Weiner and Nordin state there is no definitive link yet established between these diagnostic findings in disk degeneration and clinical signs and symptoms. As such, they proclaim DLBP remains at best a theory worthy of further investigation, but does not have the scientific support needed to guide treatment protocols.<sup>41</sup>

Many studies have examined the relative contributions of various causes of chronic LBP. The intervertebral disk is thought to play a principal role in 26% to 43% of chronic LBP cases.<sup>14,42,43</sup>

The workup of chronic LBP begins with a thorough patient history and physical examination. Imaging studies may include plain radiographs, computed tomography (CT), or magnetic resonance imaging (MRI). Relevant findings from each of these techniques and their respective implications in DLBP have been described extensively in previous publications.<sup>17,44,45</sup> Each component of the evaluation provides additional diagnostic clues that contribute to our understanding of the ailment; however, such tests have low sensitivity and specificity in determining whether the disk is a primary source of LBP.<sup>17</sup> Inclusion of provocative discography provides an additional component to the evaluation of chronic LBP, the ability to correlate pathology with symptomatology. Many believe this additional information leads to improved accuracy in diagnosing DLBP.<sup>46</sup>

## Discography

Discography is an invasive diagnostic test used in the evaluation of chronic back pain when there is persuasive evidence supporting the diagnosis of a discogenic pain origin. The procedure first appeared in medical literature in 1948 as a technique for diagnosing herniated nucleus pulposus.<sup>47</sup> During that period, imaging of the lumbar spine consisted of plain radiographs and myelography using an oil-based contrast agent, which was associated with significant complications. In the 1950s and early 1960s, discography became the preferred imaging study for detecting anatomic abnormalities within the intervertebral disk.<sup>47-49</sup> The introduction of CT in 1973, and the later development of MRI, presented less invasive, more accurate, and simpler methods for detecting internal disk disruption.<sup>50</sup> Although MRI provided superior imaging, it was not capable of assessing whether the disk produced pain.<sup>22,23,51</sup> Discography therefore remained valuable as a diagnostic tool for stimulating the disk to identify the source of pain. Several key aspects of discography have been the subject of controversy and continue

**Table 1** Patient Selection for Discography<sup>66</sup>

Further evaluation of demonstrably abnormal disks to help assess the extent of abnormality or correlation of the abnormality with the clinical symptoms. Such may include recurrent pain from a previously operated disk and lateral disk herniation.

Patients with persistent, severe symptoms in whom other diagnostic tests have failed to reveal clear confirmation of a suspected disk as a source of pain.

Assessment of patients who have failed to respond to surgical procedures to determine whether there is painful pseudarthrosis or a symptomatic disk in a posteriorly fused segment, or to evaluate possible recurrent disk herniation.

Assessment of disks before fusion to determine whether the disks within the proposed fusion segment are symptomatic and to determine whether disks adjacent to this segment are normal.

Assessment of minimally invasive surgical candidates to confirm a contained disk herniation or to investigate dye distribution pattern before chemonucleolysis or other intradiscal procedures.

to be debated. The controversies pertain to its diagnostic accuracy (sensitivity, specificity, and positive predictive value) and the potential complications that have been thoroughly described and argued in multiple publications.<sup>46,52-63</sup>

The procedure is performed by inserting a needle into the nucleus pulposus and injecting radiographic contrast material. The pattern of contrast spread is observed radiographically, providing visualization of the internal disk anatomy and identification of annular degeneration. Injection of small volumes into the nucleus causes an increase in intradiscal pressure, which provokes pain in symptomatic disks.<sup>64</sup> In this regard, discography is unique in its ability to correlate the symptom of pain with structural pathology, which is often the missing piece of the puzzle needed to confirm or reject the clinical suspicion of discogenic pain. Many spine surgeons, and interventional pain physicians, consider this additional level of diagnostic information a valuable component in the workup of an otherwise challenging condition.

**Indications**

The indications for discography are controversial and poorly defined. The decision to perform diagnostic procedures should be based on a patient’s clinical presentation. Discography is not recommended for use as a routine test in the evaluation of nonspecific LBP.<sup>65</sup> However, it is a reasonable consideration when investigating chronic LBP in patients whose history, physical examination, and imaging findings suggest a discogenic source of pain. Additionally, identification of symptomatic disks has more relevance when applied to patients for whom the anticipated course of treatment includes interventions expected to reduce disk-

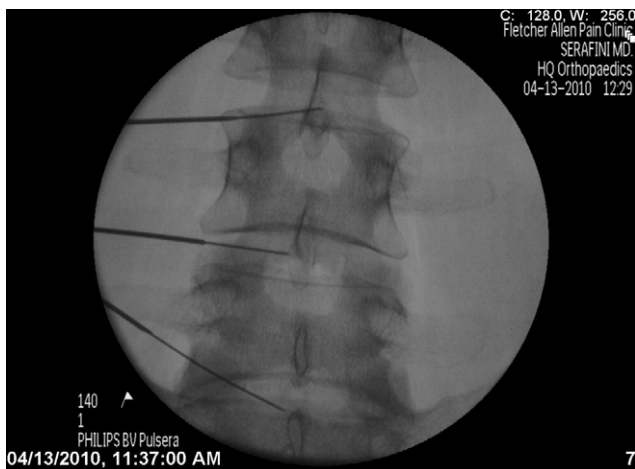related pain and disability. Discography not only assists in diagnosing the source of discogenic pain, but also provides information that may be helpful in planning interventions, guiding patient selection for surgery, and potentially predicting outcomes. The North American Spine Society issued a position statement stating that “discography should be viewed as an invasive test to be used to seek abnormality when results from other tests are equivocal or inconsistent, in a patient with symptoms severe enough to require further evaluation.”<sup>66</sup> Specific indications and contraindications for discography have been presented by Guyer and Ohnmeiss (Tables 1 and 2).<sup>66</sup> Furthermore, guidelines from the International Spinal Injection Society recommend that 2 control levels be obtained for adequate interpretation of disk stimulation.<sup>67</sup>

**Technique**

Discography is an invasive and potentially dangerous procedure that should be performed by a spine specialist or a radiologist who is experienced with the procedure. The patient should be informed of the risks, complications, benefits, alternatives, and goals of the procedure. Prior to the procedure, a detailed assessment of the patient’s pain symptoms should be obtained and all relevant imaging studies should be reviewed. This information will not only aid in selecting the best approach to each disk but it will also allow the provider to better determine whether provocation of pain is concordant or discordant with the patient’s usual symptoms. To begin, the patient is placed in the prone position and prophylactic intravenous antibiotic is administered. Monitoring should follow the sedation guidelines developed by the American Society of Anesthesiologists.<sup>68</sup> This procedure is uncomfortable, often requiring mild sedation during needle placement, followed by intravenous analgesics once the pain provocation results have been obtained. The procedure should be performed under strict sterile technique, with fluoroscopy and/or use of CT. Once appropriate sterile prep and drape have been applied, the image intensifier of the fluoroscope is positioned using oblique

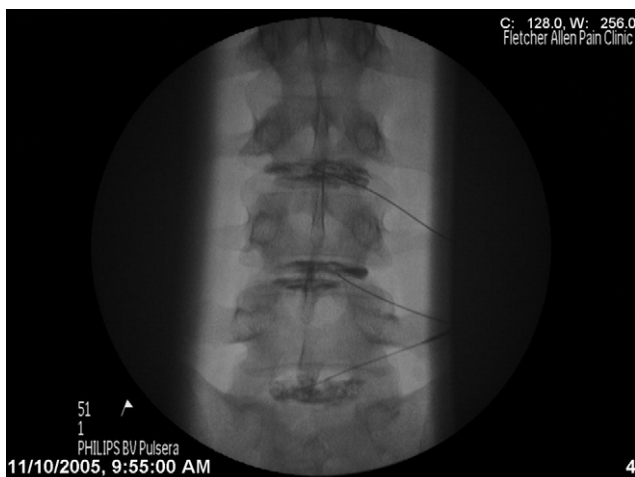
**Table 2** Contraindications for discography<sup>64,94,100</sup>

Absolute	Absence of informed consent Patients on anticoagulation therapy Patients with a known bleeding disorder Pregnancy Systemic infection Local infection over the site of injection Bony fusion that restricts access to the disk Psychiatric conditions (PTSD or schizophrenia)
Relative	Severe spinal canal stenosis at the level being evaluated <sup>101,102</sup> Allergy to radiographic contrast, antibiotic, or local

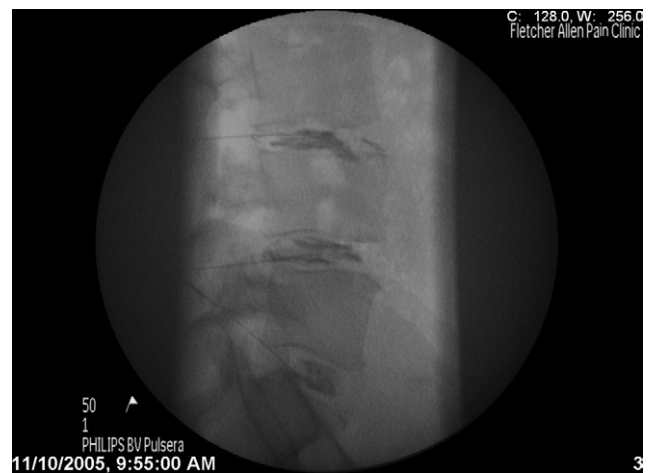

**Figure 1** Lumbar discography using a double needle technique.

and craniocaudal angulation to reveal the middle third of the intervertebral disk space and to provide visualization of the vertebral end plates adjacent to the intervertebral space being evaluated. The disk is accessible by placing the needle just anterior to the superior articulating process at the desired level. A 2-needle coaxial approach contralateral to the patient's usual pain is then used to access the nucleus pulposus. The use of antibiotics and a 2-needle technique (Figure 1) are precautionary measures proposed to reduce the risk of infection.<sup>69,70</sup> Entering from the side contralateral to the patient's usual pain is preferred to avoid confusing disk pain from procedural pain related to needle placement. Intermittent fluoroscopy should be used for advancement of the needle into each desired disk. Upon entrance into the disk, anteroposterior and lateral fluoroscopic views should be taken to confirm that the needle tip lies in the middle third of the disk. Once the final needle position has been confirmed, radiographic contrast dye, with or without an



**Figure 2** Anteroposterior image of the lumbar spine following lumbar discography at L3-4, L4-5, and L5-S1.



**Figure 3** Lateral image of the 3 lower lumbar disks after needle placement.

antibiotic, is injected (Figures 2 and 3). During the injection phase of the procedure, careful attention must be paid to interpreting the patient's pain response. Concordance is achieved if the pain and/or peripheral symptoms generated by provocation are similar in severity and location to the patient's usual pain. In addition to pain provocation, the discographer must also be cognizant of the resistance experienced during injection, amount of contrast injected, pattern of dye distribution, and extravasation. It has been proposed that the use of pressure measuring devices may improve the validity of the patient's response. While this has not yet been established, its use provides for standardization of the procedure and provides some semi-quantitative information. The International Spine Intervention Society has proposed that pressure measuring devices be used on a routine basis and have developed a scoring system for determining the results of discography.<sup>71</sup> Although analysis of the live and post injection fluoroscopic images allows for the determination of disk pathology, it has been proposed that a post discography CT be obtained for a more detailed view of the intervertebral disk architecture and the contrast distribution pattern.<sup>53</sup> Cohen et al have suggested that post discography CT imaging allows for the identification of small annular tears and can confirm the presence of a contained herniation, which may be otherwise missed by fluoroscopic imaging.<sup>53,72</sup> Therefore, post discography CT scan is useful when a detailed description of the annulus is necessary in addition to the discography findings that primarily focus on determining the presence or absence of disk symptomology. The pain distribution, and pattern, is often reported using the modified Dallas discogram scale.<sup>73</sup> The morphologic changes of degenerative disks do not always correlate with symptomatic disks. Several authors have suggested that disks with annular tears grade 3 or higher tend to produce concordant pain during the provocation phase of discography.<sup>63,74-76</sup>

**Table 3** Complications associated with discography<sup>81,82</sup>

Hematologic
Epidural hematoma
Paraspinal hematoma
Retroperitoneal hematoma
Intrathecal hemorrhage
Infectious
Discitis
Meningitis
Arachnoiditis
Osteomyelitis
Superficial infection/abscess
Paraspinal abscess
Retroperitoneal abscess
Epidural abscess
Neurologic
Nerve injury
Dural puncture headache
Intradural injection
Other
Acute lumbar disk herniation <sup>101</sup>
Needle breakage
Allergic/anaphylactic reaction to contrast, antibiotic, or local

## Complications and safety

The overall rate of reported complications from discography ranges from 0% to 2.5%.<sup>60,61,66,74-81</sup> Complications may be classified as infectious, hematological, neurological, allergic, or other (Table 3). Infection and bleeding can occur anywhere along the path of the needle, from skin to the nucleus pulposus, placed during the procedure. The most serious and frequently encountered complication is discitis with a reported incidence from 0% to 4.9% per patient or 0% to 1.3% per disk investigated.<sup>82</sup> The most common organisms identified have been *Staphylococcus epidermidis* and *Staphylococcus aureus*.<sup>80,81</sup> Preventive measures to reduce the risk of infection include employing a meticulous aseptic technique, prophylactic antibiotic administration, and use of a 2-needle technique with styletted needles to access the disk.<sup>70,80,83,84</sup> The use of a 2-needle technique was investigated by Fraser et al, who reported a reduced infection rate with a 2-needle technique using styletted needles (0.67%) compared to a single-needle technique (2.7%).<sup>70</sup> Prophylactic IV and intradiscal antibiotic administration have also been shown to reduce the risk of discitis.<sup>83,84</sup> Interestingly, while these preventive methods do appear to reduce the occurrence of discitis, neither have been shown to offer protection beyond standard sterile technique.<sup>82</sup> However, considering the relative risks involved, administering systemic and intradiscal antibiotics may be warranted, especially in patients at high risk for infection.<sup>82</sup> Hemorrhage into the subcutaneous and paraspinal structures can result in significant hematoma formation. Adherence to the guidelines set forth by the American Society of Regional Anesthesia and Pain Medicine for patients receiving anti-

thrombotic therapy may decrease the occurrence of this complication.<sup>85</sup>

## Discussion

A number of systematic reviews have attempted to interpret the results of studies evaluating discography as a predictor of surgical and nonsurgical treatment outcomes.

Resnick and coworkers produced guidelines for spinal fusion and discography based on a comprehensive review on behalf of the American Association of Neurological Surgery and the Congress of Neurological Surgeons. Their guidelines stated discography was sensitive for the diagnosis of discogenic LBP but not specific. They defined a “positive” discographic study as 1 that elicits concordant pain from a morphologically abnormal disk. Additionally, they recommended against using discography as a stand-alone test for making treatment decisions and that it should not be performed without MRI evidence of disk degeneration. They concluded that discography appears to have a role in the evaluation of patients with LBP, but be limited to the evaluation of abnormal interspaces identified on MRI, the investigation of adjacent-level disk disease, and as a means to rule out cases of nonorganic pain from surgical consideration.<sup>86</sup>

In 2007, The Washington State Health Care Authority produced a Health Technology Assessment of discography and found insufficient evidence to permit conclusions about the reliability of discography as a diagnostic test in chronic LBP or its use to predict fusion outcomes.<sup>87</sup>

Cohen et al performed a systematic review evaluating the role of spinal injections in predicting surgical outcomes. They presented findings from the available studies looking at the effect of discography on spinal fusion outcomes. They described the methodologies and results from 2 prospective and 3 retrospective outcome studies.<sup>60,74,88-90</sup> They found limited evidence that discography improves fusion outcomes in patients with DLBP, but also stated that interpretation of the data is exceptionally difficult due to methodological flaws in the studies and the lack of strong evidence supporting fusion as an effective treatment for degenerative disk disease.<sup>91</sup> This review also included an assessment of discography in presurgical screening for lumbar disk replacement. They presented findings from 25 studies evaluating disk replacement outcomes. Preoperative discography was performed in approximately one half the studies; however, these studies were not designed to compare outcomes between patients selected for surgery based on the results of discography and those selected for surgery based on other methods. Despite this limitation, an indirect comparison was performed that did not reveal evidence that preoperative discography affected outcomes.<sup>91</sup>

Walker and colleagues produced a review of the literature to assess the role of discography in presurgical screening. They included lumbar fusion studies by Derby et al<sup>74</sup>

and Carragee et al<sup>60</sup> as well as cervical fusion studies by Motimaya et al<sup>92</sup> and Whitecloud and Seago.<sup>93</sup> To summarize their conclusions, discography may improve surgical outcomes for properly selected patients. This group would include patients with persistent pain with disk abnormalities who did not have significant psychological conditions or secondary gain issues.<sup>94</sup>

In 2009 Manchikanti and coworkers published a systematic review of discography.<sup>46</sup> After a thorough review of the literature, they concluded lumbar discography may be a useful tool for evaluating chronic DLBP when performed according to the International Association for the Study of Pain (IASP). Additionally, based on modified U.S. Preventive Services Task Force evidence criteria, they found the indicated evidence to be level II-2 for the diagnostic accuracy of lumbar provocation discography using IASP standards.<sup>46</sup>

In regard to nonsurgical treatment outcomes, intradiscal electrothermal therapy, biaculplasty, and percutaneous disk decompression are among the most common nonsurgical intradiscal treatments available for DLBP. Many studies have evaluated the utility of these procedures, all of which have used discography in the patient selection process; therefore, the ability of discography to predict outcomes cannot be determined.

## Conclusions

DLBP is a major source of suffering and disability. Efforts to establish meaningful therapies for patients affected by this condition have been hindered by an incomplete understanding and a limited ability to accurately diagnose discogenic pain. Our understanding of the pathophysiology involved in disk degeneration and disk-related pain has expanded considerably over the past few decades. This knowledge has yet to lead to a proven and accepted diagnostic method for discogenic pain. Provocative discography seems to be a reasonable method for identifying painful disks, at least in theory, but without a gold standard by which to compare, the sensitivity and specificity for this technique (or any other technique) cannot be precisely established. With no promise of a gold standard on the horizon, some have proposed using therapeutic outcomes to measure the accuracy of discography. That is to say, if positive therapeutic outcomes were strongly correlated with discographic findings, by either positive or negative association, the role of discography could be clarified. However, the validity of using the outcome of a controversial treatment, such as spinal fusion for discogenic pain, as a gold standard for discography, is also a questionable concept.<sup>62</sup> Surgery may be warranted to provide mechanical stabilization in many clinical circumstances; however, the surgical treatment of discogenic pain has been disappointing.<sup>95-97</sup> Furthermore, even proven therapies are unlikely to produce positive outcomes, beyond a placebo effect, when treatment

is undertaken for inaccurate diagnoses. The primary role of discography is to determine whether a patient's chronic LBP has a discogenic component. Unfortunately, there is a great deal of uncertainty surrounding the utility of discography. The results from primary studies evaluating the effect of discography on outcomes are often contradictory.<sup>60,74,75,88-90,98,99</sup> Systematic reviews, and efforts to pool data from these studies, have produced inconsistent conclusions. Ongoing investigation on the role of intradiscal pressures, clinical biomarkers, functional anesthetic discography, and functional imaging may help clinicians distinguish true discogenic pain from morphologically abnormal, yet asymptomatic, intervertebral disks.

## References

1. McBeth J, Jones K: Epidemiology of chronic musculoskeletal pain. *Best Pract Res Clin Rheumatol* 2:403-425, 2007
2. Rubin DI: Epidemiology and risk factors for spine pain. *Neurol Clin* 25:353-371, 2007
3. Freburger JK, Holmes GM, Agans RP, et al: The rising prevalence of chronic low back pain. *Arch Intern Med* 169:251-258, 2009
4. Harkness EF, Macfarlane GJ, Silman AJ, et al: Is musculoskeletal pain more common now than 40 years ago? Two population-based cross-sectional studies. *Rheumatology (Oxford)* 44:890-895, 2005
5. Cassidy JD, Côté P, Carroll LJ, et al: Incidence and course of low back pain episodes in the general population. *Spine* 30:2817-2823, 2005
6. Pengel LH, Herbert RD, Maher CG, et al: Acute low back pain: systematic review of its prognosis. *BMJ* 327:323, 2003
7. Carey TS, Garrett JM, Jackman AM: Beyond the good prognosis. Examination of an inception cohort of patients with chronic low back pain. *Spine* 25:115-120, 2000
8. Von Korff M, Saunders K: The course of back pain in primary care. *Spine* 21:2833-2839, 1996
9. Andersson GB: Epidemiological features of chronic low-back pain. *Lancet* 354:581-585, 1999
10. Croft PR, Macfarlane GJ, Papageorgiou AC, et al: Outcome of low back pain in general practice: A prospective study. *BMJ* 316:1356-1359, 1998
11. Chou R, Atlas SJ, Stanos SP, Rosenquist RW: Nonsurgical interventional therapies for low back pain: A review of the evidence for an American Pain Society clinical practice guideline. *Spine* 34:1078-1093, 2009
12. Bogduk N: Musculoskeletal pain: Toward precision diagnosis: Progress in pain research and management, in Jensen TS, Turner JA, Wiesenfeld-Hallin Z (eds): *Proceedings of the 8th World Congress on Pain*. Seattle, WA, IASP, 1997, pp 507-525
13. Boyajian SS: Using image-guided techniques for chronic low back pain. *J Am Osteopath Assoc* 107:ES3-ES9, 2007 (suppl 6)
14. Manchikanti L, Singh V, Pampati V, et al: Evaluation of the relative contributions of various structures in chronic low back pain. *Pain Physician* 4:308-316, 2001
15. Borkan JM, Koes B, Reis S, Cherkin DC: A report from the Second International Forum for Primary Care Research on Low Back Pain. Reexamining priorities (A report from the Second International Forum for Primary Care Research on Low Back Pain. Reexamining priorities). *Spine* 23:1992-1996, 1998
16. Bogduk N: The causes of low back pain. *Med J Aust* 156:151-153, 1992

17. Hancock MJ, Maher CG, Latimer J, et al: Systematic review of tests to identify the disc, SII or facet joint as the source of low back pain. *Eur Spine J* 16:1539-1550, 2007
18. DePalma MJ, Ketchum JM, Saullo T: What is the source of chronic low back pain and does age play a role? *Pain Med* 12:224-233, 2011
19. Ohnmeiss DD, Vanharanta H, Ekholm J: Relation between pain location and disc pathology: A study of pain drawings and CT/discography. *Clin J Pain* 15:210-217, 1999
20. Saifuddin A, Emanuel R, White J, et al: An analysis of radiating pain at lumbar discography. *Eur Spine J* 7:358-362, 1998
21. Endean A, Palmer KT, Coggon D: Potential of magnetic resonance imaging findings to refine case definition for mechanical low back pain in epidemiological studies: A systematic review. *Spine* 36:160-169, 2011
22. Jensen MC, Brant-Zawadzki MN, Obuchowski N, et al: Magnetic resonance imaging of the Lumbar Spine in People without Back Pain. *N Engl J Med* 331:69-116, 1994
23. Boden SD, Davis DO, Dina TS, et al: Abnormal magnetic-resonance scans of the lumbar spine in asymptomatic subjects. A prospective investigation. *J Bone Joint Surg Am* 72:403-408, 1990
24. Saal JS: General principles of diagnostic testing as related to painful lumbar spine disorders: A critical appraisal of current diagnostic techniques. *Spine* 27:2538-2545, 2002
25. Malinsky J: The ontogenetic development of nerve terminations in the intervertebral discs of man. (Histology of intervertebral discs, 11th communication). *Acta Anat (Basel)* 38:96-113, 1959
26. Kang CH, Kim YH, Lee SH, et al: Can magnetic resonance imaging accurately predict concordant pain provocation during provocative disc injection? *Skeletal Radiol* 38:877-885, 2009
27. Groen GJ, Baljet B, Drukker J: Nerves and nerve plexuses of the human vertebral column. *Am J Anat* 188:282-296, 1990
28. Hirsch C, Ingelmark BE, Miller M: The anatomical basis for low back pain. *Acta Orthop Orthop Scand* 33:1-17, 1963
29. Bogduk N: Nerves of the Lumbar Spine. *Clinical Anatomy of Lumbar Spine and Sacrum* (ed 4). New York, Churchill Livingstone, 2005, pp 123-139
30. Coppes MH, Marani E, Thomeer RT, et al: Innervation of annulus fibrosis in low back pain. *Lancet* 336:189-190, 1990
31. Bogduk N: The innervation of the lumbar spine. *Spine* 8:286-289, 1983
32. Edgar MA: The nerve supply of the lumbar intervertebral disc. *J Bone Joint Surg Br* 89:1135-1139, 2007
33. Freemont AJ, Peacock TE, Goupille P, et al: Nerve ingrowth into diseased intervertebral disc in chronic back pain. *Lancet* 350:178-181, 1997
34. Vanharanta H, Sachs BL, Spivey MA, et al: The relationship of pain provocation to lumbar disc deterioration as seen by CT/discography. *Spine* 12:295-298, 1987
35. Freemont AJ, Watkins A, Le Maitre C, et al: Nerve growth factor expression and innervation of the painful intervertebral disc. *J Pathol* 197:286-292, 2002
36. Coppes MH, Marani E, Thomeer RT, et al: Innervation of "painful" lumbar discs. *Spine* 22:2342-2349, 1997
37. Burke JG, Watson RW, McCormack D, et al: Intervertebral discs which cause low back pain secrete high levels of proinflammatory mediators. *J Bone Joint Surg Br* 84:196-201, 2002
38. Peng B, Wu W, Hou S, et al: The pathogenesis of discogenic low back pain. *J Bone Joint Surg Br* 87:62-67, 2005
39. Nerlich AG, Weiler C, Zipperer J, et al: Immunolocalization of phagocytic cells in normal and degenerated intervertebral discs. *Spine* 27:2484-2490, 2002
40. Zhang YG, Gou TM, Gou X, et al: Clinical diagnosis for discogenic low back pain. *Int J Biol Sci* 5:647-658, 2009
41. Weiner SS, Nordin M: Prevention and management of chronic back pain. *Best Pract Res Clin Rheumatol* 24:267-279, 2010
42. Schwarzer AC, April CN, Derby R: The prevalence and clinical feature of internal disc disruption of patients with chronic low back pain. *Spine* 20:1878-1883, 1995
43. Zhou Y, Abdi S: Diagnosis and minimally invasive treatment of lumbar discogenic pain—a review of the literature. *Clin J Pain* 22:468-468, 2006
44. Guyer RD, Ohnmeiss DD: The role of discography in the evaluation of degenerative disc disease. *Semin Spine Surg* 19:72-77, 2007
45. Knaub RKM: Clinical and diagnostic evaluation of low back pain. *Semin Spine Surg* 20:93-101, 2008
46. Manchikanti L, Glaser SE, Wolfer L, et al: Systematic review of lumbar discography as a diagnostic test for chronic low back pain. *Pain Physician* 12:541-559, 2009
47. Lindblom K: Diagnostic puncture of the intervertebral discs in sciatica. *J Orthod Scand* 17:231-239, 1948
48. Feinberg SB: The place of discography in radiology as based on 2320 cases. *Am J Radiol* 92:1275-1281, 1964
49. Collis JS Jr, Gardner WJ: Lumbar discography. An analysis of one thousand cases. *J Neurosurg* 19:452-461, 1962
50. Saboeiro GR: Lumbar discography. *Radiol Clin North Am* 47:421-433, 2009
51. Stadnik TW, Lee RR, Coen HL, et al: Annular tears and disk herniation: Prevalence and contrast enhancement on MR images in the absence of low back pain or sciatica. *Radiology* 206:49-55, 1998
52. Levin JH: Prospective, double-blind, randomized placebo-controlled trials in interventional spine: What the highest quality literature tells us. *Spine J* 9:690-703, 2009
53. Cohen SP, Larkin TM, Barna SA, et al: Lumbar discography: A comprehensive review of outcome studies, diagnostic accuracy, and principles. *Reg Anesth Pain Med* 30:163-183, 2005
54. Shah RV, Everett CR, McKenzie-Brown AM, et al: Discography as a diagnostic test for spinal pain: A systematic and narrative review. *Pain Physician* 8:187-209, 2005
55. Carragee EJ, Tanner CM, Yang B, et al: False-positive findings on lumbar discography. Reliability of subjective concordance assessment during provocative disc injection. *Spine* 24:2542-2547, 1999
56. Carragee EJ, Tanner CM, Khurana S, et al: The rates of false-positive lumbar discography in select patients without low back symptoms. *Spine* 25:1373-1380, 2000
57. Carragee EJ, Paragioudakis SJ, Khurana S: 2000 Volvo Award winner in clinical studies: Lumbar high-intensity zone and discography in subjects without low back problems. *Spine* 25:2987-2992
58. Carragee EJ, Chen Y, Tanner CM, et al: Provocative discography in patients after limited lumbar discectomy: A controlled, randomized study of pain response in symptomatic and asymptomatic subjects. *Spine* 25:3065-3071, 2000
59. Carragee EJ, Alamin TF: Discography. A review. *Spine J* 1:364-372, 2001
60. Carragee EJ, Lincoln T, Parmar VS, et al: A gold standard evaluation of the "discogenic pain" diagnosis as determined by provocative discography. *Spine* 31:2115-2123, 2006
61. Carragee EJ, Alamin TF, Carragee JM: Low-pressure positive discography in subjects asymptomatic of significant low back pain illness. *Spine* 31:505-509, 2006
62. Buenaventura RM, Shah RV, Patel V, et al: Systematic review of discography as a diagnostic test for spinal pain: an update. *Pain Physician* 10:147-164, 2007
63. Walsh TR, Weinstein JN, Spratt KF, et al: Lumbar discography in normal subjects. A controlled, prospective study. *J Bone Joint Surg Am* 72:1081-1088, 1990
64. Kallewaard JW, Terheggen MA, Groen GJ, et al: Discogenic low back pain. *Pain Pract* 10:560-579, 2010
65. Practice Guidelines for Chronic Pain Management: An Updated Report by the American Society of Anesthesiologists Task Force on Chronic Pain Management and the American Society of Regional Anesthesia and Pain Medicine. *Anesthesiology* 112:810-833, 2010
66. Guyer RD, Ohnmeiss DD. NASS: Lumbar discography. *Spine J* 3:11S-27S, 2003 (suppl)
67. Endres S, Bogduk N: Practice Guidelines and Protocols: Lumbar Disc Stimulation. *Proceeding of the International Spinal Injection*

- Society 9th Annual Scientific Meeting, September 14-16, 2001 Boston, MA, pp 56-75
68. American Society of Anesthesiologists, Task Force on Sedation and Analgesia by Non-Anesthesiologists; Practice guidelines for sedation and analgesia by non-anesthesiologist. *Anesthesiology* 96:1004-1017, 2002
  69. Rathmell JP: Lumbar discography and intradiscal electrothermal therapy, in Rathmell JP (ed): *Atlas of Image-Guided Interventions in Regional Anesthesia and Pain Medicine*. Philadelphia, PA, Lippincott Williams & Wilkins, 2006, pp 101-112
  70. Fraser RD, Osti OL, Vernon-Roberts B: Discitis after discography. *J Bone Joint Surg Br* 69:26-35, 1987
  71. Endres S, Bogduk N: Lumbar disc stimulation, in Bogduk N (ed): *International Spine Intervention Society: Practice Guidelines and Protocols*. San Francisco, CA, International Spine Intervention Society, 2005, pp 20-46
  72. Cohen SP, Williams S, Kurihara C, et al: Nucleoplasty with or without intradiscal electrothermal therapy (IDET) as a treatment for lumbar herniated disc. *J Spinal Disord Tech* 18:S119-S124, 2005 (suppl)
  73. Sachs BL, Vanharanta H, Spivey MA, et al: Dallas discogram description. A new classification of CT/discography in low-back disorders. *Spine* 12:287-298, 1987
  74. Derby R, Howard MW, Grant JM, et al: The ability of pressure-controlled discography to predict surgical and nonsurgical outcomes. *Spine* 24:364-371, 1999
  75. Derby R, Lee SH, Kim BJ, et al: Pressure-controlled lumbar discography in volunteers without low back symptoms. *Pain Med* 6:213-221, 2005
  76. Vanharanta H, Sachs BL, Ohnmeiss DD, et al: Pain provocation and disc deterioration by age. A CT/discography study in a low-back pain population. *Spine* 14:420-423, 1989
  77. Guyer RD, Collier R, Stith WJ, et al: Discitis after discography. *Spine* 13:1352-1354, 1988
  78. Kinard RE: Diagnostic spinal injection procedures. *Neurosurg Clin N Am* 7:151-165, 1996
  79. Tehranzadeh J: Interventional procedures in musculoskeletal radiology: Discography 2000. *Radiol Clin North Am* 36:463-495, 1998
  80. Willems PC, Jacobs W, Duinkerke ES, et al: Lumbar discography: should we use prophylactic antibiotics? A study of 435 consecutive discograms and a systematic review of the literature. *J Spinal Disord Tech* 17:243-247, 2004
  81. Kapural L, Cata JP: Complications of percutaneous techniques used in the diagnosis and treatment of discogenic lower back pain. *Tech Reg Anesth Pain Manag* 11:157-163, 2007
  82. Sharma SK, Jones JO, Zeballos PP, et al: The prevention of discitis during discography. *Spine J* 9:936-943, 2009
  83. Osti OL, Fraser RD, Vernon-Roberts B: Discitis after discography. The role of prophylactic antibiotics. *J Bone Joint Surg Br* 72:271-274, 1990
  84. Pobiet RS, Schellhas KP, Pollei SR, et al: Diskography: infectious complications from a series of 12,634 cases. *AJNR Am J Neuroradiol* 27:1930-1932, 2006
  85. Horlocker TT, Wedel DJ, Rowlingson JC: Regional anesthesia in the Patient Receiving antithrombotic or Thrombolytic Therapy: American Society of Regional Anesthesia and Pain Medicine Evidence-Based Guidelines (3rd ed). *Reg Anesth Pain Med* 35:164-101, 2010
  86. Resnick DK, Choudhri TF, Dailey AT, et al: Guidelines for the performance of fusion procedures for degenerative disease of the lumbar spine. Part 6: Magnetic resonance imaging and discography for patient selection for lumbar fusion. *J Neurosurg Spine* 2:662-669, 2005
  87. Health Technology Assessment, Washington S, in Health Care Authority (ed): *Spinal Fusion and Discography for Chronic Low Back Pain and Uncomplicated Lumbar Degenerative Disc Disease*. Olympia, WA, ECRI Institute, 2007
  88. Coulhoun E, McCall IW, Williams L, et al: Provocation discography as a guide to planning operations on the spine. *J Bone Joint Surg Br* 70:267-271, 1988
  89. Esses SI, Botsford DJ, Kostuik JP: The role of external spinal skeletal fixation in the assessment of low-back disorders. *Spine* 14:594-601, 1989
  90. Madan S, Gundanna M, Harley JM, et al: Does provocative discography screening of discogenic back pain improve surgical outcome? *J Spinal Disord Tech* 15:245-251, 2002
  91. Cohen SP, Hurley RW: The ability of diagnostic spinal injections to predict surgical outcomes. *Anesth Analg* 105:1756-1775, 2007
  92. Motimaya A, Arici M, George D, et al: Diagnostic value of cervical discography in the management of cervical discogenic pain. *Conn Med* 64:395-398, 2000
  93. Whitecloud TS, Seago RA: Cervical discogenic syndrome. Results of operative intervention in patients with positive discography. *Spine* 12:313-316, 1987
  94. Walker J, El Abd O, Isaac Z, Muzin S: Discography in practice: a clinical and historical review. *Curr Rev Musculoskelet Med* 1:69-83, 2008
  95. Fairbank J, Frost H, Wilson-MacDonald J, et al: Randomised controlled trial to compare surgical stabilisation of the lumbar spine with an intensive rehabilitation programme for patients with chronic low back pain: The MRC spine stabilisation trial. *BMJ* 330:1233, 2005
  96. Gibson JN, Waddell G: Surgery for degenerative lumbar spondylosis: Updated Cochrane review. *Spine* 30:2312-2320, 2005
  97. Brox JI, Sørensen R, Friis A, et al: Randomized clinical trial of lumbar instrumented fusion and cognitive intervention and exercises in patients with chronic low back pain and disc degeneration. *Spine* 28:1913-1921, 2003
  98. Blumenthal SL, Baker J, Dossett A, et al: The role of anterior lumbar fusion for internal disc disruption. *Spine* 13:566-569, 1988
  99. Gill K, Blumenthal SL: Functional results after anterior lumbar fusion at L5-S1 in patients with normal and abnormal MRI scans. *Spine* 17:940-942, 1992
  100. Fenton DS, Czervionke LF (eds): *Image-Guided Spine Intervention*. Philadelphia, PA, Saunders, 2003
  101. Poynton AR, Hinman A, Lutz G, et al: Discography-induced acute lumbar disc herniation: a report of five cases. *J Spinal Disord Tech* 18:188-192, 2005
  102. Laun A, Lorenz R, Agnoli AL: Complications of cervical discography. *J Neurosurg Sci* 25:17-20, 1981