
TUTORIAL

Chronic Female Pelvic Pain—Part 1: Clinical Pathoanatomy and Examination of the Pelvic Region

Gail Apte, PT, ScD*; Patricia Nelson, PT, ScD[†]; Jean-Michel Brismée, PT, ScD*; Gregory Dedrick, PT, ScD*; Rafael Justiz III, MD[‡]; Phillip S. Sizer Jr., PT, PhD*
*Center for Rehabilitation Research, Texas Tech University Health Science Center, Lubbock, Texas; [†]Department of Physical Therapy, Eastern Washington University, Spokane, Washington; [‡]Saint Anthony Pain Management, Oklahoma City, Oklahoma, U.S.A.

■ **Abstract:** Chronic pelvic pain is defined as the presence of pain in the pelvic girdle region for over a 6-month period and can arise from the gynecologic, urologic, gastrointestinal, and musculoskeletal systems. As 15% of women experience pelvic pain at some time in their lives with yearly direct medical costs estimated at \$2.8 billion, effective evaluation and management strategies of this condition are necessary. This merits a thorough discussion of a systematic approach to the evaluation of chronic pelvic pain conditions, including a careful history-taking and clinical examination. The challenge of accurately diagnosing chronic pelvic pain resides in the degree of peripheral and central sensitization of the nervous system associated with the chronicity of the symptoms, as well as the potential influence of the affective and biopsychosocial factors on symptom development as persistence. Once the musculoskeletal origin of the symptoms is identified, a clinical examination schema that is based on the location of primary onset of

symptoms (lumbosacral, coccygeal, sacroiliac, pelvic floor, groin or abdominal region) can be followed to establish a basis for managing the specific pain generator(s) and manage tissue dysfunction. ■

Key Words: myofacial pain, pelvic pain, signs and symptoms, female examination

INTRODUCTION

Pain in the pelvic region can arise from musculoskeletal, gynecologic, urologic, gastrointestinal, and/or neurological conditions. Such pain can involve both the somatic (T12-S5) and visceral (T10-S5) systems, making the differential diagnosing challenging.¹⁻³ There are several possible explanations for chronic pelvic pain (CPP) that include disorders of the urogynecological system, gastrointestinal system, musculoskeletal system, and of the nervous system. Of the various diagnoses, the most frequently noted are endometriosis (33%), and other gynecological conditions (33%).⁴ Conversely, a lack of pathology is found in 33% to 35% of women with pelvic pain who have received diagnostic laparoscopy.^{4,5} Pelvic congestion syndrome with dilated pelvic veins resulting in impaired blood

Address correspondence and reprint requests to: Phillip S. Sizer Jr., PT, PhD, OCS, FAAOMPT, Professor & Program Director, Doctorate of Science Program in Physical Therapy, Director, Clinical Musculoskeletal Research Laboratory, 3601, 4th Street, Lubbock, TX 79430, U.S.A. E-mail: phil.sizer@ttuhsc.edu.

DOI: 10.1111/j.1533-2500.2011.00465.x

flow may contribute to selected cases of CPP.^{6,7} Janicki proposes that CPP may be a form of complex regional pain syndrome or it may be a form of central sensitization of the nervous system.^{5,8} The challenge in identifying the pain generators and effectively treating this condition explains the tendency for pelvic pain to become chronic and the frustration associated with its management both for the patient and the healthcare provider.⁹ While the history may indicate pain from a pelvic source, consideration for referred pain from structures outside the pelvic region should not be overlooked.¹⁰ The clinical examination should include a thorough medical, surgical, social, and behavioral history, as well as the evaluation of the gynecological, gastrointestinal, urologic, neurologic, and musculoskeletal systems from the thoracic cage to the thigh regions.

Acute pelvic pain can often be accurately diagnosed and effectively treated. However, CPP is more challenging to diagnose and treat because the specific pathological processes responsible for the origin of the pain are more difficult to identify. While pelvic pain can be intermittent or constant, it is its potential unremitting nature that leads to disability. Moreover, a history of physical, psychological, and sexual abuse can factor into the pathogenesis. Due to a lack of understanding regarding the pathophysiology of CPP, treatment goals are usually limited to management of pain and accompanying complications. Currently, the main approaches to treatment include counseling or psychotherapy, hormone therapy, attempts to provide reassurance, using laparoscopy to exclude serious pathology, and surgical intervention. Pain management interventions may be of assistance in pharmaceutical management, performing nerve blocks, neural ablative procedures, or neuromodulation for pain relief. Musculoskeletal causes of pelvic pain, as well as referred pain into the musculoskeletal system, may be successfully managed with conservative measures. However, many healthcare professionals have limited experience with contemporary management strategies and may not consider referral for conservative management of CPP.

Definition of Terms

The careful use of standardized terms is important for optimal communication among practitioners. For this discussion, *pelvic pain* is defined as pain arising from the visceral or somatic system and encompasses structures supplied by the nervous tissue from the 10th thoracic spinal level and below. *Pelvic pain syndrome*

has a recurrent or persistent pain associated with symptoms, suggesting involvement of the musculoskeletal, gynecological, urological or gastrointestinal systems and the absence of inflammation or other specific pathology.¹¹ *CPP* is defined as nonmalignant pain perceived in the structures related to the pelvis that has been present for > 6 months or has a nonacute pain mechanism of shorter duration.¹² *Pelvic floor* refers to the fascial and muscular layers that span the bony outlet of the pelvis.^{13–15}

Identification of normal pelvic floor function is typically described in terms of the continence mechanism; however, there are sexual and postural support requirements for the pelvic floor that have been less well identified in the literature. The association of pelvic pain with urologic symptoms has been well described. The association of pelvic pain with urological symptoms has been identified for the subset of chronic pain patients with painful bladder conditions, such as interstitial cystitis and painful bladder syndrome. In those women with the interstitial cystitis, 87% presented with pelvic floor dysfunction.¹⁶ This does not suggest a causative relationship, but rather an overlap of several conditions. While 94% of women with this pain described urologic voiding or storage symptoms, only 43% with voiding or storage symptoms also described pain.¹⁴ With this extent of overlap in a population possessing pelvic pain as the diagnosis, it is necessary to evaluate all functions of the pelvic floor structures (support, storage, and sexual) to establish a function-based diagnosis and treatment.¹²

PATHOANATOMICAL CONSIDERATIONS

Descriptions of the pathoanatomy related to the thoracic, lumbar, and sacroiliac complexes have been previously discussed.^{17–19} For the sake of this article, a pathoanatomy discussion of the distinctive structures germane to pelvic ring/floor afflictions is merited.

Coccygeal Anatomy

Pelvic ring architecture, that includes sacroiliac joint and pubic symphysis, has been described in detail by others, as has the thoracic and lumbar spine.^{20–23} We will complete our knowledge of the pelvic floor region by discussion of coccygeal anatomy. The coccyx consists of 4 bony segments, where the first coccygeal cornua located just distal to the sacral cornua complete the sacral hiatus. The sacrococcygeal ligaments, which

span between distal sacrum and coccyx and stabilize the sacrococcygeal joint, cover the sacral hiatus of the spinal canal. An intervening disc can be observed between the S5 vertebra and the coccyx, as well as between the first two bony segments of the coccyx.²⁴ The S5 spinal nerve exits thru the lateral foramen found between the sacrum and coccyx. The first and second coccygeal bony segments are potentially mobile and predisposed to pathological hypermobility. Maigne considers pathological coccygeal hypermobility as a coccygeal flexion angle $> 25^\circ$ in a sitting position as compared to a standing position. Coccygeal hypomobility is considered as a seated coccygeal angle of $< 5^\circ$ when compared with standing.²⁴ A dynamic seated lateral radiograph can help find the angle in contrast to the same angle in standing.²⁴ Noteworthy are the origins of the levator ani muscles and a portion of the gluteus maximus at the coccyx. Coccygectomy has been proposed for severe cases of coccydynia.^{25,26} While successful for severe cases, resection releases a portion of the muscular insertions of the levator ani and gluteus maximus at the coccyx, which may lead to dysfunction of the pelvic floor. As yet, long-term effects of coccygectomy on pelvic floor muscle function have not been studied.

Muscular Anatomy

The anatomy of transverse abdominis (TrA), oblique abdominals (internal oblique and external oblique; IO and EO, respectively), gluteus maximus (GM), gluteus medius (GMed), and latissimus dorsi (LD) has been well described.^{27,28} In this section, we will discuss the anatomy and function of the pelvic floor as it relates to the understanding of the stabilizing effect of TrA, internal oblique (IO), external oblique (EO), gluteus maximus (GM), gluteus medius (GMed), latissimus dorsi (LD), erector spinae (ES), and multifidus (Mf), as these all have been shown to work concurrently when stabilizing the pelvic ring.²⁹⁻³¹ When referring to the pelvic floor, the area defined as the perineum is bordered by the pubic symphysis anteriorly, the inferior pubic rami and ischial rami anterolaterally, the ischial tuberosities laterally, the sacrotuberous ligaments posterolaterally, and the coccyx and sacrum posteriorly. The space created by these borders is divided into regions by an imaginary line drawn between the anterior aspects of ischial tuberosities (Figures 1 and 2).

A triangle described anterior to this imaginary line is called the urogenital triangle with the urethra and

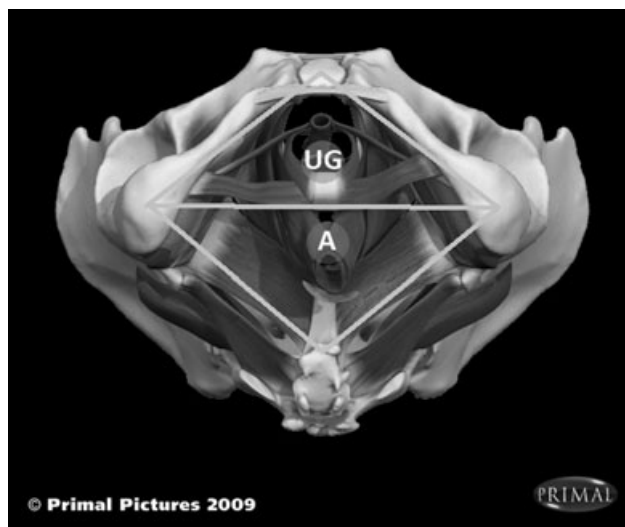


Figure 1. Regions pelvic floor: (UG) urogenital triangle; (A) anal triangle. Primal pictures 2009.

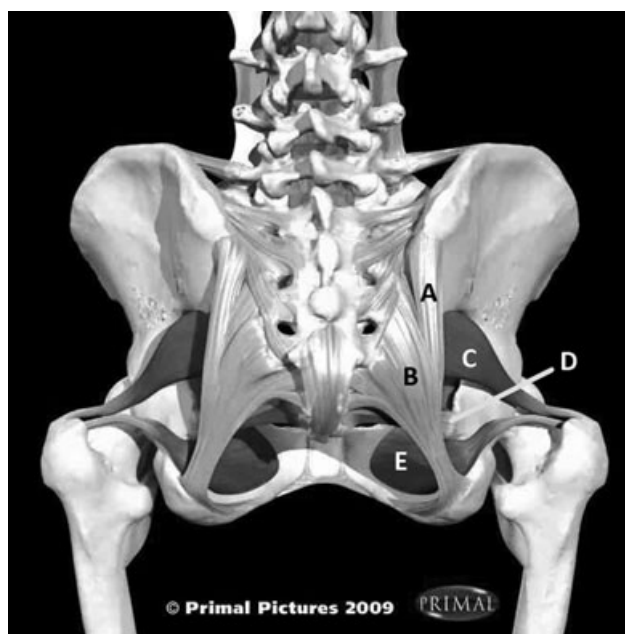


Figure 2. Urogenital triangles: (A) long dorsal sacroiliac ligament, (B) sacrotuberous ligament, (C) piriformis, (D) sacrospinous ligament, (E) obturator internus. Primal pictures 2009.

vagina interrupting the pelvic floor muscles through this triangle. The perineal membrane extends bilaterally from the anterior triangle. The triangle posterior to this line is the anal triangle, with the anus interrupting the pelvic floor muscles in this region. The perineal body is found at the midpoint of this line between the anus and perineal membrane. The perineal body is a mass of collagenous and elastic fibers, as well as smooth and skeletal muscle fibers.³² It has been considered to be the

attachment site for bulbospongiosus, superficial and deep transverse perineal muscles and the external anal sphincter. A recent study proposed that the perineal body is the site at which the perineal muscles cross from one side to the other within the pelvic floor.³³ It is a particularly important structure in women because it is the final support for the pelvic viscera.^{34,35} The disruption of the perineal body that occurs during childbirth can cause a vaginal prolapse due to the loss of support to the posterodistal wall of the vagina. Episiotomy, or surgical perineal cutting performed during childbirth to prevent a jagged perineal tearing, can lead to a weakening of the perineal body if not adequately repaired.^{32,34} The perineal body can be further weakened by trauma other than childbirth, inflammation, or infection.³⁶ Over time, pelvic pain may develop due to a constant barrage of noxious stimuli from the prolapsed organ to the dorsal horn of the spinal cord, resulting in upregulation of the dorsal horn.³⁷

The pelvic floor consists of several muscles arranged in deep and superficial layers that behave similar to a sling that supports the pelvic contents (Figures 3 and 4).²⁰ The deep levator ani muscles, which are referred to as the pelvic diaphragm, include the pubococcygeus, puborectalis/iliococcygeus, and the coccygeus. The levator ani muscles have their origin from the arcus tendineus that extends from the pubic bone anteriorly to the spine of the ischium posteriorly. These muscles insert into the perineal body, coccyx, anococcygeal ligament, vaginal walls, rectum, and anal canal.²⁰

The coccygeus muscle has its origin at the ischial spine and inserts into the inferior end of the sacrum. Activation of this muscle produces coccygeal flexion and assists the levator ani in supporting the pelvic viscera. The superficial layers that comprise the urogenital diaphragm include the ischioavernosus, bulbospongiosus, and superficial transverse perineal muscles. The external urethral and anal sphincter muscles are considered to be a part of the pelvic floor. Both layers are surrounded by fascia that is connected to the fascia surrounding the pelvic organs, thus lending to their support. Weakening of the levator ani muscles, as well as the support structures of the rectum, vagina, uterus, and the bladder, can lead to structural prolapse.³⁸⁻⁴⁰

The predisposition to prolapse appears to be multifactorial. Soderberg et al.⁴¹ reported a 30% lower collagen concentration in younger women with vaginal prolapse and an age-related decrease in collagen concentration in support structures. Tinelli et al.⁴² argued that, as a result of aging where collagen content and estrogen status decreases along with reduced ability of muscles to strengthen, it may not be possible for a woman to reverse the effects of prolapse with surgery. The same may apply to attempts at improving pelvic floor strength with an exercise program. Conversely, Skilling and Petros^{43,44} each suggested a squatting position to increase the collagen content of the pelvic floor structures. However, the question arises whether

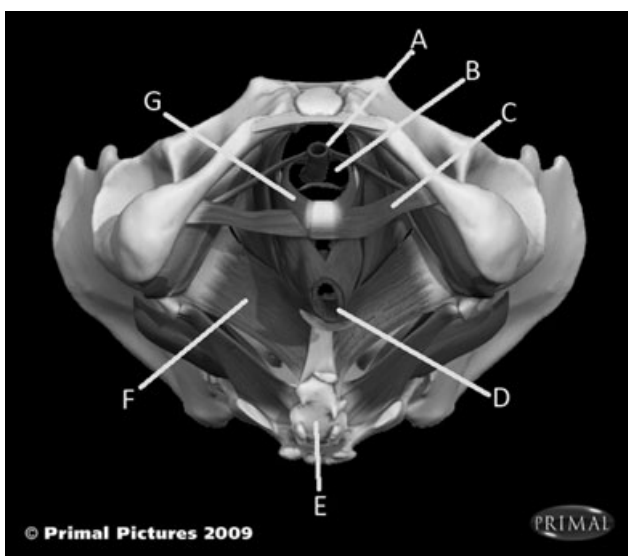


Figure 3. Urogenital triangles contents: (A) urethra, (B) vagina, (C) superficial and deep transverse perineal, (D) anus, (E) coccyx, (F) levator ani, (G) bulbospongiosus. Primal pictures 2009.

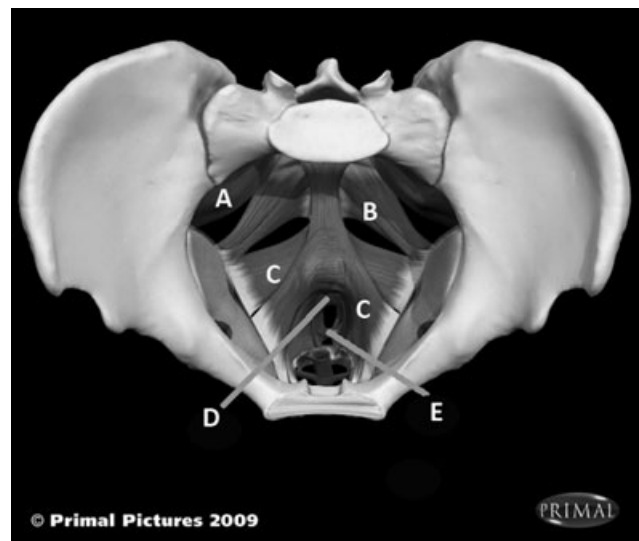


Figure 4. Pelvic floor muscles (in order from posterior wall to anterior wall): (A) piriformis, (B) coccygeus, (C) levator ani [pubococcygeus, puboanalis, pubovaginalis], (D) internal anal sphincter, (E) perineal body. Primal Pictures 2009.

prolapse of the urinary bladder, uterus or the bowels leads to the pelvic pain. As of yet, the evidence is not clear regarding this association.

The pelvic floor muscles form the base of a cylinder that comprised the diaphragm cranially, the TrA anteriorly and laterally, and thoracolumbar fascia posteriorly. They function to support the pelvic organs while closing the urethra and anus. Pelvic floor muscle contraction leads to increased pressure within the vagina and anus, lending to the maintenance of continence through increased abdominal pressure. This behavior is important for forceful functions such as expiration, coughing, sneezing, urinating, defecating, and heavy lifting with the arms. To support this, investigators found that the pubococcygeus activity increases during coughing, whereas puborectalis activity increases during lifting.²⁰ Thus, movements of the pelvic floor and abdominal muscles must be coordinated to maintain continence and prevent prolapse of the pelvic organs.

Abdominal activity appears to act synergistically with pelvic floor activation. Several studies have documented the activation of the pelvic floor concurrently with activation of the TrA muscle.⁴⁵⁻⁴⁸ Here, a feed-forward mechanism functions to create increased muscular activity in the TrA muscle just prior to the pelvic floor movement, as evidenced by increased TrA electromyographic (EMG) activity recorded just prior to movement initiation. In a similar fashion, Sapsford and Hodges⁴⁵ found that activity in the abdominal muscles creates activity in the pelvic floor muscles.

Finally, pelvic floor function appears to relate to the stability of the sacroiliac joint and pelvic ring. In a cadaveric study of 18 specimens, Pool-Goudzwaard et al.³¹ demonstrated that pelvic floor muscle contraction appeared to stabilize the sacroiliac joint, lending to greater pelvic stability. Other investigators have confirmed that the activation of pelvic floor muscles stiffens the sacroiliac joints and pelvic ring.^{48,49} The Active Straight Leg Raise test, as proposed by Mens, has been used to assess pelvic ring instability. The test is considered positive when the patient feels apprehensive in lifting or sustaining an active straight leg raise or reports pain in the pelvic area. This appears to occur in response to reduced influence of the pelvic floor muscles on pelvic ring stability and indicates a loss of load transfer ability between the trunk and the lower extremity.^{50,51} This loss of load transfer ability appears to be associated with both pelvic and lumbosacral pain, further supporting the importance of a well-functioning pelvic floor muscle system.

General Neuroanatomical Considerations

The neuroanatomy of the thoracic, lumbar, SIJ/pubic symphysis/pelvic ring, and hip has been previously described.⁵² Similarly, a detailed discussion of pathology, testing, and treatment of these areas is available.^{17-19,53} Specifically, disc, joint, muscular, and neurologic pathologies can contribute to pelvic pain. Sacral spinal nerves innervate the pelvic floor structures, where afflictions in this region can potentially produce buttock and or perineal pain that accompanies local pelvic pain. Additionally, one must consider the contribution of the various thoracic, lumbar, pelvic, pelvic floor, and visceral structures to pain generation in the pelvic region. The clinician must decide if evaluation of the thoracolumbar spine, pelvic ring, and the hip is warranted as part of pelvic floor evaluation.

Musculoskeletal afflictions found in nearby structures can refer pain to the pelvic region. For example, hip pathologies that include hip arthrosis and labrum tears are known to refer pain deep in the groin. The anterior SIJ is innervated by nerves from L3 to S2 and the posterior SIJ by S1 and S2. Thus, pain from the SIJ can be experienced in the buttock, upper thigh, and groin. Similarly, the pubic symphysis is innervated by ilioinguinal nerve, where irritation to this structure is known to produce local pelvic, lower abdominal, and groin pain.

Chronic cases of pelvic pain may be due to viscerosomatic convergence, which is a possible explanation for patient complaints of pelvic pain that originates in the urogynecological or gastrointestinal systems.⁵⁴ As a result it may be possible for pain that originates in the pelvic viscera innervated by sacral sympathetic segments to be experienced in the sacral somatic regions. For example, the lower thoracic and upper lumbar spinal cord contributes innervation to the lower abdominal pelvic areas. Sympathetic ganglia from this region and from the sacral and pelvic regions contribute to the superior and inferior hypogastric plexi, which innervate the pelvic organs. These visceral afferents reach the upper lumbar/lower thoracic spinal cord levels at the same levels as the visceral fibers from lower lumbar discs. With long standing pain, sensory convergence of information from autonomic afferents may lead to somatic symptoms, while afference from the somatic lumbar structures may promote pain in the pelvic region.

Nerve entrapment syndromes are not uncommon in the pelvic region, especially as a result of trauma, such

as stretching, compression with hypoxia, blunt trauma, fibrosis, and entrapment within a surgical suture. An understanding of the specific regional neuroanatomical relationships of the nerve structures is critical to precision in interventional and rehabilitation management. Regional localization can promote management accuracy, which will become relevant in Part II. The innervation of the pelvic area are the iliohypogastric, ilioinguinal, lateral femoral cutaneous, and genitofemoral nerves originating from T12 to L3, as well as the nerve to the levator ani and pudendal nerves originating from S2 to S5. These nerves share the same spinal cord levels as the pelvic organs innervated by the superior and inferior hypogastric plexi. Thus, nerve entrapments can refer pain to the pelvic region, as exemplified by obturator or genitofemoral nerve entrapments referring pain to the upper medial thigh and labia majora, respectively.

Iliohypogastric Neuroanatomy

The iliohypogastric nerve originates from T12 to L1 spinal cord segments, converging on dorsal horn structures shared with the ipsilateral ovary and distal fallopian tube. This nerve passes through the psoas muscle and the TrA, coursing medial and deep to the internal oblique at the level of the iliac crest to exit the pelvis midway between the mid-axillary line on the iliac crest and the anterior superior iliac spine.⁵⁵ It divides into a cutaneous branch to the anterior abdominal wall about 1 cm superior to the inguinal canal, a motor branch that innervates the TrA and internal oblique, and a sensory branch that innervates the groin and pubic symphysis. Suture ligation or fibrotic entrapment from postoperative scar that involves the abdominal and pelvic structures in this region has a potential to entrap the nerve. The patients will often complain of a pulling sensation with movement, accompanied by a throbbing sensation at rest. Differential diagnoses should include neuropathies of the ilioinguinal and genitofemoral nerves, as there is an overlap of innervation.

Ilioinguinal Neuroanatomy

The ilioinguinal nerve originates from L1 to L2 and converges on dorsal horn structures shared with the proximal fallopian tubes and uterine fundus. It enters the inguinal canal approximately 2 cm medial to the anterior superior iliac spine to travel along the canal.

It exits through the superficial inguinal ring to become a sensory nerve to the overlying skin. It supplies sensory innervation to the groin, mons, labia, and inner thigh.

The most common injury is entrapment by suture ligation in the lateral edges of Pfannenstiel's incision, or trauma induced during needle bladder suspension.⁵⁶ Unfortunately, diagnosis of entrapment is delayed because of a similar symptomatology to other uterine pathology. Symptoms include disturbed sensation over the skin supplied by the ilioinguinal nerve.

Genitofemoral Neuroanatomy

The genitofemoral nerve has its origins from the same levels (L1 to L2) as the ilioinguinal nerve, thus converging on dorsal horn structures shared with the proximal fallopian tube and uterine fundus. The nerve courses through the psoas muscle and emerges near its medial border at the level of the third and fourth lumbar vertebrae.²⁰ The nerve divides into genital and femoral branches above the inguinal ligament, where the genital branch supplies the skin of the mons pubis and labia majora. Conversely, the femoral branch supplies the skin of the femoral triangle.⁵⁵ The most common injury in this region involves the right genitofemoral nerve.⁵⁶ This injury may occur as a result of postappendectomy perineural fibrosis at the nerve's exit through the psoas muscle. Hernia repair can produce genitofemoral neuropathy on either side by suture or staple entrapment at the inguinal canal. Complaints consist of burning paresthesias and pain in the groin, labia, and medial thigh.

Obturator Neuroanatomy

Within the fibro-osseous tunnel at the pubic rami, the obturator nerve, arising from ventral rami from L2 to L4, divides and sends a branch to the obturator externus muscle, an anterior branch that has motor branches to the adductor longus, adductor brevis and gracilis, and sensory branches to the distal medial two-thirds of the thigh. The anterior division of the obturator nerve can sometimes send a motor branch to the pectineus and a sensory supply to the hip, but this supply is inconsistent. The posterior branch of the obturator nerve sends motor fibers to the adductor magnus and sensory fibers to supply the knee joint capsule, cruciate ligaments, and synovial membranes.

Patients with obturator nerve entrapment complain of painful spasms of the adductor muscle of the thigh and sensory loss in the medial thigh region.⁵⁷

Lateral Femoral Cutaneous Neuroanatomy

Although the lateral femoral cutaneous nerve does not innervate any structures in the pelvic region, its anatomy is important to appreciate because of convergence on shared dorsal horn cells with the uterine fundus and lower uterus.²⁰ The lateral femoral cutaneous nerve arises from L2 to L3 and courses inferolaterally in the iliacus muscle to pass under the inguinal ligament. Depending on whether the nerve passes behind or through the inguinal ligament, it may be vulnerable to mechanical compression.

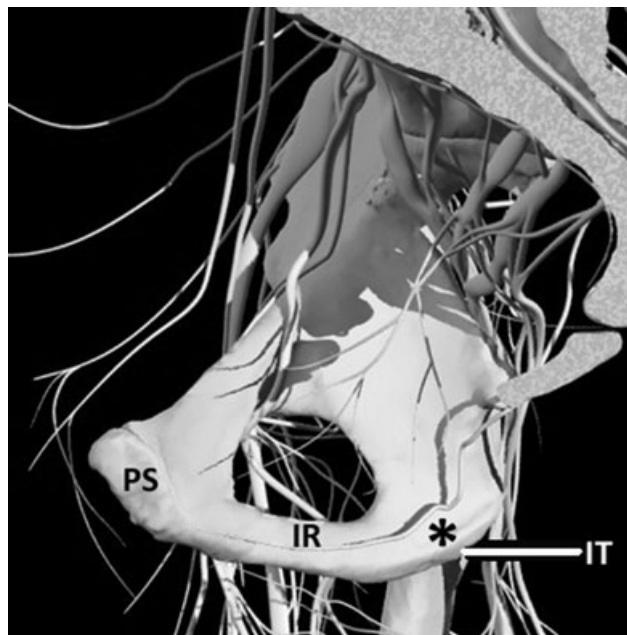
Lateral femoral cutaneous neuropathy, also termed meralgia paraesthetica, produces pain and numbness in the upper outer thigh. Decompression at the inguinal ligament will typically alleviate these symptoms. At least 80 different etiologies for this neuropathy have been described. Pressure from tight or wide belts, tight pants, postsurgical abdominal scars, pregnancy, iliac bone graft harvest, ascites, obesity, abdominal/pelvic mass, and metabolic neuropathies can serve as the etiology of this condition.⁵⁶

Neuroanatomy of the Pudendal Nerve and Nerve to Levator Ani

Innervation of pelvic floor muscles is via the nerve to the levator ani and via the pudendal nerve to the perineal muscles, as well as external urethral and anal sphincters.⁵⁸⁻⁶⁰

The pudendal nerve comprised the anterior branches of the ventral rami from S2 to S4. It exits the pelvis through the greater sciatic foramen and reenters the pelvis thru the lesser sciatic foramen, passing between the sacrospinous ligament anteriorly and sacrotuberous ligament posteriorly, while wrapping behind the ischial spine.

Once in the perineal area, the pudendal nerve travels within the Alcock's (pudendal) canal, a tunnel created by the overlying parietal fascia covering the obturator muscle (Figure 5). The nerve is accompanied by the pudendal artery, vein, and nerve, to the obturator internus through the pudendal canal. The pudendal canal is located on the medial aspect of the obturator internus covered by the obturator fascia. Once the nerve reenters the pelvis it divides into



© 2003 Primal Pictures Ltd.

Figure 5. Course of pudendal nerve at ischial tuberosity: IT = ischial tuberosity; IR = ischial ramus; PS = pubic symphysis; pudendal nerve (*) courses through Alcock's canal, noting the course on the medial side of the ischial tuberosity and ramus. This course creates a vulnerability for nerve compression/irritation during a seated posture. Primal Pictures 2009.

three branches that are named for the structures they innervate.

The first branch of the pudendal nerve, the nerve to the levator ani, arises just proximal to the pudendal canal.⁶¹ and supplies motor function to the external anal sphincter and perianal skin. The second branch, also known as the perineal branch, provides sensation to the perineal skin, vaginal tissues, and vestibule, as well as motor fibers to the external urethral sphincter. The third branch innervates the anal sphincters. The pudendal nerve provides sensory innervation to an area defined by the inferior pubic ramus, labio-crural folds, and the intergluteal fold.²⁰ The pudendal nerve converges on the area of the dorsal horn shared with the cervix, uterosacral, and vulvovaginal area. The pudendal nerve is a mixed sensory and motor nerve, often lending to concurrent motor and sensory symptoms. As a consequence, a sacral motor neuropathy produces abnormal bladder and bowel function.

The separate branches of the levator ani nerve, arising from S3 to S4, consistently innervates the levator ani muscle, whereas the pudendal nerve innervates the levator ani in approximately 50% of subjects.⁵⁸⁻⁶⁰ The nerve to the levator ani is located along the visceral

aspect of the levator ani muscle and is not easily accessible in contrast to the pudendal nerve. Some find branches arising from the pudendal nerve, whereas others only find the cranial supply to the pelvic floor structures from ventral rami of S3 to S5, termed the levator ani nerve.⁶²

The pudendal nerve can be traumatized throughout the perinatal experience, thus leading to CPP.^{63,64} A prolonged second stage of labor during vaginal delivery, a third degree tear through the perineal body and a high neonatal birth weight appear to traumatize the nerve, as evidenced by increased pudendal nerve terminal motor latency.⁶⁵⁻⁶⁷ Dietz and Schierlitz⁶⁵ has reported a limited recovery in this nerve function during the first 3 months postpartum but no change thereafter. Surgical pudendal nerve injuries have been reported with sacrospinous vaginal vault suspension, vaginal laceration repairs, and various types of episiotomies.^{61,68} Other patients have developed pudendal neuropathy after straddle injuries, prolonged motor-cycle or bicycle riding, and laser treatment to the vulva and perineum.

While the levator ani nerve has not been studied as extensively as the pudendal nerve, it is conceivable that, due to compression or stretching of the nerve from the pressure of the neonate, it may be traumatized during a prolonged second-stage labor in a similar fashion to the pudendal nerve. Wallner et al.⁵⁹ further hypothesized that, due to the location of the levator ani nerve, the nerve may be more vulnerable than the pudendal nerve that is better protected within the pudendal canal, especially in the proximity of the sacrospinous ligament.

Pudendal nerve pain is experienced unilaterally or bilaterally. The painful areas include the labia, perineum, and the anorectal region. The symptoms of this neuropathy range from constant burning to intense stabbing pain. It is exacerbated or provoked by sitting and relieved by standing, recumbency or sitting on a surface that removes pressure on the ischial tuberosities, such as a toilet seat. Diagnosis can be easily made with a pudendal nerve block.

A potential cause of pudendal nerve pain is entrapment between the sacrospinous and sacrotuberous ligaments. Movement of the sacroiliac joint is described as nutation and counternutation. The function of the sacrospinous and sacrotuberous ligaments is to constrain nutation, which is considered to be a locked or stable position.¹⁷ Tightening of these ligaments narrows the space between them where the pudendal

nerve passes on its way back into the pelvis. Counternutation, which is considered to be an unstable position of the joint, has been implicated in posterior pelvic pain of pregnancy⁶⁹

Selected authors postulate that in some individuals the pudendal nerve may be at risk as a result of athleticism or increased general activity as youngsters.⁷⁰ Activities that include repeated squatting appear to be especially insulting to the nerve, as this maneuver entraps the pudendal nerve as it courses between these ligaments. Straining for constipation may also cause damage to the nerve in response to neural stretching. Treatment for pudendal neuropathy includes avoidance of deep squatting maneuvers and sitting on a cutout pad that avoids pressure at the ischial tuberosities.⁷⁰

REGIONAL NEUROANATOMY

Pelvic visceral innervation occurs via the superior and inferior hypogastric plexi. The superior hypogastric plexus comprised sympathetic fibers from lumbar splanchnic nerves. Each sympathetic ganglion communicates with somatic nerves via the gray ramus communicans. The superior hypogastric plexus is composed of lumbar sympathetic chains and branches of the aortic plexus and parasympathetic nerves originating from the S2 to S4 nerve roots. This plexus divides into the right and left hypogastric nerves that descend to reach the inferior hypogastric plexus. The hypogastric nerves are predominantly sympathetic. The superior hypogastric plexus sends branches to the ureteral and ovarian plexi, the sigmoid colon, and the plexus surrounding the internal iliac arteries.²⁰

The sympathetic sacral splanchnic nerves arise from S1 to S4 sympathetic ganglia and combine with the pelvic splanchnic nerves. Pelvic splanchnic nerves originate from S2 to S4. The postganglionic sympathetic fibers from the sacral splanchnic nerves and parasympathetic fibers from the pelvic splanchnic nerves, along with contribution of the superior hypogastric plexus via the hypogastric nerves, make up the inferior hypogastric plexus.

Visceral Innervation

Visceral disorders will not be discussed here, except as they relate to viscerosomatic, viscerovisceral, and visceroviscerosomatic convergence.^{71,72} Visceral nerves converge on the same spinal cord levels as somatic

nerves at the thoracolumbar and sacral spinal cord. Due to temporal summation and convergence of afferent input within the spinal cord, sensory information can create perceptual representations outside the native visceral sensory areas. This can result in pain felt in the somatic areas as result of increased sensory information from the visceral system. Given enough time, trigger points can develop in peripheral somatic tissue in response to this increased nociceptive visceral input.⁷³ This is referred to as viscerosomatic convergence. Similar behavior occurs where one visceral system refers symptoms to an adjacent visceral system, leading to viscerovisceral convergence.⁷² Pathology within any visceral structures could increase the perception of pain from another adjacent organ system, thus contributing to CPP.

This convergence response can be used therapeutically. It may be possible to influence pain from the pelvic region by applying appropriate treatment modalities to the thoracolumbar and sacral somatic regions. For example, investigators found that the application of acupuncture needles to acupuncture point Bl-33 for 10 minutes for 5 weeks was effective in reducing pain of intrapelvic venous congestion.⁷⁴ This illustrates the concept of using convergence to reduce pain of intrapelvic venous congestion.

Rectal Neuroanatomy

The rectum is continuous with the sigmoid colon; at its distal end is the anus with an internal and external anal sphincter that maintains continence. The rectum receives sympathetic innervation from lumbar splanchnic nerves and parasympathetic innervation from pelvic splanchnic nerves (previously discussed).

Urinary Tract—Bladder, Urethra

The bladder is a hollow organ with strong muscular walls that demonstrate the ability to distend. When empty, its position is within the lesser pelvis, lying posterior and superior to the pubic bones. Its position changes with the amount of filling and the state of the pelvic organs surrounding it. Ligaments do not support the bladder but the urethra is well supported by the pubovesical ligaments. The innervation of the bladder is via parasympathetic fibers derived from the pelvic splanchnic nerves and sympathetic fibers from T11 to L2. This dual innervation allows the bladder to fill, store, and empty urine, resulting in a status where the

bladder never fully empties. Continence involves voluntary cognitive processes. During the filling phase, the sympathetic fibers signal the internal urethral sphincter to maintain closure while the parasympathetic fibers keep the bladder walls relaxed allowing the filling to continue. Urinary urgency corresponds to this filling, while cognitive processes allow voluntary inhibition of urge. During the emptying phase, the opposite is seen, where parasympathetic fibers induce bladder wall contraction and sympathetic fibers allow urethral relaxation.

Pelvic Floor Innervation

It is important for us to understand the innervation of the pelvic floor, particularly the close relationship of somatic and visceral nerves within the pelvis and pelvic floor. The levator ani nerve (S3 to S5; previously discussed) consistently innervates the levator ani muscle, whereas the pudendal nerve does not. The pudendal nerve innervates the external urethral and anal sphincters, perineal muscles (bulbospongiosus, ischiocavernosus, deep and superficial transverse perineal muscles), clitoris, and skin.^{20,75}

The coccygeal plexus is formed from the anterior division primarily of S5 with a small contribution from S4 that joins with the coccygeal nerve. The plexus lies anterior to the sacrum and coccyx and posterior to the pelvic organs, this area is rich in somatic and autonomic nerve endings. The autonomic structures are the ganglion impar and the superior and inferior hypogastric plexi. The S4, S5, and coccygeal nerves are sensory nerves, where stimulation of S4 might evoke vaginal pain and stimulation of S4, S5, and coccygeal roots may evoke anal and coccygeal pain. In some patients, the coccyx pain is experienced in the S3 distribution because of the S3 innervation of vascular structures in this area.

Genital Organs

The genital organs include the uterus, fallopian tubes, ovaries (adnexa), and the vagina. The vagina is a musculomembranous tube approximately 7 to 9 cm long.²⁰ The vagina opens into the vestibule (the area between the labia minora) at one end and ends at the cervix. At its proximal end, the vaginal fornices are recesses around the cervix. The anterior vagina shares a common wall with the bladder. Posteriorly, the vagina shares a wall with the anal canal, rectum, and

rectouterine pouch. Laterally, the vagina is surrounded by the levator ani muscles, the visceral pelvic fascia, and the ureters.

Sympathetic innervation of the entire vagina occurs via fibers origination in the lower thoracic and upper lumbar segments. Parasympathetic innervation is supplied via the pelvic splanchnic nerves from S2 to S4. Only the distal 20% to 25% of the vagina exhibits somatic innervation via the pudendal nerve. The vaginal walls can become detached from their connection with the visceropelvic fascia and levator ani as a result of prolonged second-stage labor during vaginal delivery or due to forceps delivery, both potentially resulting in prolapse and or pudendal neuropathy as well as neuropathy of the nerve to the levator ani.^{65,76–80}

The uterus is a thick-walled, hollow muscular organ that lies in the lesser pelvis on top of the bladder, exhibiting the ability to distend and change position with the filling of the bladder and rectum. It is supported by the broad ligament that can be visualized as a trampoline surrounding the uterus and by the round ligaments at its anterolateral margins. Cardinal ligaments (transverse cervical ligaments) that extend from the cervix and lateral walls of the vagina to the lateral walls of the pelvis support the uterus and the cervix. A second ligamentous system, the uterosacral ligaments, attach from the superior and slightly posterior aspect of the lateral cervix to the middle of the sacrum, which are palpable during rectal exam. Innervation of the uterus is sympathetic from the lumbar splanchnic nerves, along with parasympathetic fibers of the pelvic splanchnic nerves from S2 to S4. Uterine nociceptive afference travels via sympathetic fibers to reach the upper lumbar and lower thoracic spinal ganglia.

The fallopian tubes extend laterally from the uterine horns and open into the peritoneal cavity near the ovaries, contained within the broad ligament and arching posterosuperiorly over the ovaries. Innervation of the fallopian tubes comes from the sympathetic fibers from T11 to L1, while parasympathetic innervation originates from the pelvic splanchnic nerves. The ovaries are almond shaped glands suspended by the broad ligament.²⁰ Innervation of the ovaries emerges from sympathetic and parasympathetic fibers (previously described).

A thorough understanding of the previously described anatomy can serve as a foundation for effective clinical examination of CPP. Once examined, understanding the same anatomy can positively influence

successful management of the patient's clinical condition.

CLINICAL EXAMINATION OF PELVIC PAIN

As many as 9 million women between the ages of 15 and 50 suffer from CPP in the United States, which represents 15% of the female population.^{9,81} CPP is nearly as prevalent as low back pain and asthma with direct costs estimated at \$2.8 billion and indirect costs at \$555 million.⁹ Of these individuals, up to 60% do not have a specific diagnosis and up to 20% have not received any diagnostic testing.⁸² CPP occurs with regular frequency in women during reproductive years and later. The resulting disability and distress is significant in terms of economic, social, and personal costs. Patients with CPP often elect to seek surgical management in an attempt to relieve their symptoms. While 10% to 15% of patients' consultations to gynecologists are due to CPP, 40% of gynecologic laparoscopic procedures are performed to ascertain a gynecological cause for CPP vs. other gastrointestinal, genitourinary, and skeletal conditions.⁸¹ Hysterectomy for treatment of CPP leaves 25% to 40% of women with unchanged symptoms after surgery, suggesting a nongynecologic cause of the pelvic pain.⁸¹

The pathogenesis of CPP is poorly understood. The combined difficulty of accurately diagnosing the painful mechanism(s) coupled with the prevalence of CPP suggests the need for better educating healthcare providers in effective examination and differential diagnosis aimed at determining the underlying pathophysiological mechanisms responsible for the patient's pelvic pain.⁸³ This necessitates that skilled practitioners be able to evaluate each system individually, as well as appraise the collective interaction of these systems in producing the patient's symptom profile.^{9,83} Primary medical practitioners and consulting physical therapists each have a unique role to play in the assessment and management of CPP conditions with the common goals of restoring function and improving the health status of their patients.

Intake History

To identify the cause of dysfunction, a systematic approach to examination is essential. Such an approach provides the practitioner the best ability to: (1) appraise relevant historical findings; (2) clinically

examine their patients by anatomical region; (3) identify specific mechanical and motor control dysfunctions; (4) determine the level of nervous system sensitization; and (5) evaluate the extent of biopsychosocial involvement in the patient's condition. Once examined, the appropriate team of practitioners can be selected for optimizing patient management.

The clinical examination of a patient with CPP entails the clinician obtaining from the patient a thorough history of the condition and the patient completing selected outcome measures. Due to the breadth of problems that can be classified as CPP, the following specific examination sequence may be delivered during multiple clinical sessions. The first session should focus on the intake information and determination about the need for referral to a specialty medical practitioner. If the symptoms are deemed to have a musculoskeletal component, that portion of the clinical examination is performed during the same session. The second session should be aimed at providing feedback on system sensitivity after the initial examination, along with the analysis of the specific pelvic floor muscular structures. When performing an examination, the clinician should be aware of the possible history of physical, psychological, or sexual abuse. If present, then the clinician should be prepared to refer the patient to the appropriate clinical specialist. In addition, the clinician should be familiar with visceral and somatic pain referral patterns, along with components aimed at screening for red flags.

Timing of onset and location of pain are important. For example, it is helpful to know whether dyspareunia is experienced during sexual relationships at the introitus or deep within the vagina. Generally, the clinician should consider the following questions as one method of organizing the patient history:

Who? This question identifies specifics regarding population prevalence and influence of ethnicity, along with the condition's relationship with age factors, menses, psychological history, and physical or mental abuse.

What? This question identifies the type of pain the patient experiences, exploring both the quality and quantity of symptoms.

When? This question identifies the timeliness of the symptoms, including time of onset, along with which times/activities the symptoms appear to exacerbate. This includes time of day/night, vaginal penetration,

sexual intercourse, defecation, urination, stress, activity, and postural position.

Where? This question asks for the location of initial onset of pain, location of current pain, and location of primary and secondary symptom presentation.—The following are included in this description: local, referred (visceral innervation patterns, viscerosomatic referral, viscerovisceral referral, visceroviscerosomatic referral, convergence), and neurogenic.

Why? This question explores the causes for the symptoms. The patient should be queried regarding concomitant organ system symptoms.

To what extent? The question focuses on the severity, irritability, nature, and stage of pain.

It is necessary to evaluate the contribution of biopsychosocial factors and central processing dysregulation to the CPP in order to insure developing an optimal management strategy. Biopsychosocial assessment can be initiated during intake questioning. Use of the *Beck Depression Inventory* and *McGill pain questionnaire*, as well as the SF-12 or SF-36, can provide a limited measure of the patient's affective state. While not specific to pelvic pain, the *Roland Morris Disability Questionnaire* and *Oswestry Disability Index* may help to ensure the completeness of biopsychosocial assessment of CPP patients with associated lumbar spine dysfunction. The use of the *Pelvic Floor Impact Questionnaire* and *Pelvic Floor Distress Inventory* allow more condition-specific assessments.⁸⁴ Use of the *visual analog scale* can be adapted to measure pain, functional impairments, or mood states and is a more patient-specific measure that can assist with outcome analysis. The assessment of the patient's (1) home or work environment, (2) cognitive strategies, and (3) coping style can be elucidated through specific questions (see <http://www.IPPS.org> for intake form) or verbal cueing during patient history intake. Once these measures are completed and scored, the resulting data can be combined with outcomes from specific clinical tests and measures to formulate an understanding of peripheral pain generator(s) and the scope of the biopsychosocial and physiologic processes involved in the patient's CPP profile.

The International Pelvic Pain Society has developed an examination process and recommends its use for all healthcare professionals who are involved in managing patients with pelvic pain (<http://www.IPPS.org>). While lengthy and difficult for patients to fully complete, this

evaluation serves to capture the patient's historical features that are key to the differential diagnostic process.

Nader suggested that the patient's history is often the key to interpreting the physical examination and should include the character, intensity, radiation, and daily chronological pattern of the patient's pain.^{9,10} The historical pain characteristics may help differentiate between somatic and visceral influences. Somatic pelvic pain is typically well defined, sharp and localized to the area of pathology.¹⁰ However, in the chronic state, the somatic mechanisms of peripheral and central sensitization can lead to symptoms that are more diffuse and difficult to alter with mechanical testing or treatment.^{85,86} As a result, visceral pelvic pain is poorly localized, vague in nature, and described as an aching, cramping or squeezing that waxes and wanes, while often referred to other areas.^{10,87}

Chronic pain paradigms point to a dysfunction of peripheral and/or central sensory signaling, as well as central processing mechanisms.^{88,89} As a consequence, the patient's attention and focus paid to the painful symptoms appear to enhance the development of chronic pain.^{89,90} Thus, management of these painful conditions requires a biopsychosocial approach that includes thorough assessment and treatment of the structural pathology, as well as interventions to assist the emotional, psychological, motivational, and cognitive factors contributing to the ongoing pain.⁹¹⁻⁹³ In order to appropriately direct the management, one should begin to understand the historical features associated with each subsystem.

Regional Clinical Examination

The goal of clinical examination is to determine the specific pain generator(s), identify suboptimal or pathological movement control strategies and establish functional outcomes from which the patient's care plan can be developed. In the absence of red flags that include fracture, tumor, infections or serious unexplained disease, the clinician should proceed with the differential diagnosis. CPP is multifactorial and the clinical examination should differentiate those patients with peripheral mechanical pain and somatic sensitization from those patients with central processing dysregulation or affective system involvement as the primary feature responsible for their condition. The lack of intake measures that can clearly differentiate these populations necessitates the use of a systematic clinical examination to differentiate the patient who is

appropriate for specific mechanical treatment from the one who is not. Once the diagnosis and characteristics of the dysfunction have been identified, management strategies specific to each patient's needs may be applied.^{90,94-96}

Clinical examinations schema is based on the location of initial pain onset. Using this information, the clinician selects the primary area for examination: (1) sacroiliac joint and pelvic ring; (2) pelvic floor; (3) thoracolumbar and lumbar spine region; (4) coccyx; (5) hip region to include the groin, buttock, and greater trochanteric areas; or (6) suprapubic/abdominal region (Appendix S1). Consideration should be given to the symptoms that originated during pregnancy and a higher priority given to evaluation of the pelvic girdle in this population. In addition, the list of possible considerations that must be included in the differential diagnostic process is listed by location and should be considered for the likelihood of each condition based on the patient age, history, and presentation (Appendix S2). Once the primary onset area has been identified during the history, the clinician can begin the clinical examination sequence of that state.

During the examination, the clinician should take note of pain behavior (timing, nature, and intensity), coping strategies, and movement strategies utilized while simultaneously assessing the specific mechanical test results. This process provides the basis for assessment of the secondary pain disease state as well as the cognitive and affective strategies incorporated by the patient.

An examination of the sacroiliac joint may be merited for the CPP patient. As suggested by Laslett and Sizer, reliability of sacroiliac joint testing is improved with a cluster of at least three positive pain provoking tests.^{17,97,98} The testing sequence of the sacroiliac and pelvic ring regions includes:

1. *Sacroiliac joint provocative tests*⁹⁹—The clinician observes for a cluster of at least three positive (pain provoking) tests. These tests include the following:
 - (i) *Distraction*: The patient is supine. The clinician applies pressure through the bilateral ASIS's in a dorsal and lateral direction.
 - (ii) *Compression*: The patient is in side lying. The clinician applies a medially directed pressure over the lateral aspect of the uppermost ilia.
 - (iii) *Thigh thrust*: The patient is supine. The

tested thigh is flexed to 90°. The test is performed with a direct long axis pressure through the thigh.

(iv) *Sacral thrust*: The patient is prone. The clinician applies a direct ventral pressure over the sacrum.

(v) *Gaenslens-nutation*: The patient is supine or side lying. The clinician fully flexes one hip (test side) and thigh while fully extending the other hip (for stability).

(vi) *Gaenslens-counter-nutation*: The same movement is performed with the leg positions in the opposite direction.

2. *Active straight leg raise*^{50,94,100,101}—The clinician observes for patient difficulty in performing the test, with the effort of leg lift improving after pelvic stabilization using belt application.
3. *Resisted hip adduction*¹⁰¹—Weakness of adductors predicts disease severity in pelvic girdle pain of pregnancy. The clinician retests after applying a pelvic stabilization belt. If weakness improves with belt, positive symphysis or pelvic ring load transfer dysfunction is suspected.
4. *Specific palpation* of the pelvic ligaments^{94,100}—The long dorsal sacroiliac ligament is palpated from posterior superior iliac spine to the S3S4 level; the sacrotuberous and sacrospinous ligaments are palpated dorsally from the ischial tuberosity to the sacrum and iliac spine to the sacrum, respectively.
5. *Motor control strategies*—The clinician assesses motor control strategies for force closure of the pelvis and support to the thoracolumbar spine during general body movements, transition, and functional activities.^{48,94,102} This assessment includes the following: (1) activation of the TrA and PFM, (2) implementation of diaphragmatic breathing, (3) utilization of balanced activation between abdominal muscles and trunk extensors, and (4) observation for aberrant movement of spine (see full description under Motor Control Assessment).

Once the sacroiliac joint and pelvic ring examinations are complete, specific assessment of the pelvic floor is included as necessary.^{103,104} The need to analyze specifically the pelvic floor is based on findings in

the history suggesting perineal pelvic floor dysfunction, such as hesitancy with voiding or other alterations in sphincter function. Pelvic floor assessment is only conducted with consent of the patient.

A complete examination sequence and the differential diagnostics for the lumbar spine have been previously described.¹⁸ When screening the lumbar spine, the patient is asked to denote any symptom provocation during the following movements; (1) lumbar active flexion, with addition of neck flexion; (2) lumbar extension; (3) lumbar side bend to each side; and (4) slump or straight leg raise testing.¹⁰⁵ If none of these tests provokes the patient's familiar pain, then assessment of other musculoskeletal structures is warranted.

A complete description of hip complex examination has been previously described.¹⁰⁶ A screening exam to rule out hip pathology should include: (1) passive hip flexion in supine, (2) passive internal rotation in supine and prone, and (3) labrum tests with axial and internal rotation overpressure. If these tests do not provoke the patient's familiar pain or reflect relevant joint dysfunction, then further assessment of additional musculoskeletal structures is warranted.

Examination of the Pelvic Floor

Myofascial dysfunction of the pelvic floor has been implicated in CPP conditions as both a causative and associated factor responsible for pain.^{107,108} While the etiology of myofascial pain is not well understood, symptomatic treatment of these painful myofascial conditions has been a focus of management in multiple conditions of chronic pain.^{109–111}

The literature from the 1970s described pelvic floor muscular abnormalities related to the urethral syndromes and interstitial cystitis. While the process of somatic structures leading to wind up within the central and peripheral nervous systems has been documented, the process of visceral structures leading to somatic symptoms has only been described in the context of myofascial pain syndrome.^{112,113} While local treatment can be effective for pain management and improvement of function, treating the cause of the dysfunction is most likely to contribute to longstanding improvements.^{114,115}

The implementation and timing of a pelvic floor examination can depend on the order of symptom onset (Table 1). If the CPP patient experiences pelvic floor pain as the first and foremost symptom, then the pelvic floor should be examined in a thorough fashion

Table 1. Oxford Scale for Grading Pelvic Floor Muscle Strength¹⁰⁴

Grade	Characteristics
0	No discernible contraction
1	A flicker or pulsation is felt under the examiners finger
2	Muscular tension is noted under the examiners finger, without discernible lift
3	Muscle tension with lifting of muscle belly is noted. Elevation of the posterior vaginal wall into examiners finger. Observation of "in-drawing" of perineal body and anus possible
4	Increased muscle tension with elevation of posterior vaginal wall against resistance
5	Strong, squeezing muscle contraction against vigorous resistance. Suction effect with examining finger drawn further into introitus

early in the examination sequence. If the pelvic floor symptom onset is delayed and the symptoms are secondary to other symptoms (such as posterior pelvic, groin, or coccygeal pain), then the pelvic floor examination can be conducted after a thorough examination of the other potential pain generators is conducted. The examination should include specific consent by the patient and presence of a secondary party in the examination room. The perineal examination can be used to educate the patient about their perineal anatomy and function, as well as to gather objective data by providing a mirror for patient use.

While it is generally easier to perform the examination in the supine position, the question arises whether there is a difference in measured pelvic floor muscle strength in the supine vs. standing position. Investigators measured pelvic floor strength in supine and standing positions using a digital exam and a perineometer and did not find significant differences in

muscles strength in supine or standing positions, thus suggesting that clinicians can perform the exam in supine or standing position.¹¹⁶

For Pelvic Floor examination, the observation of the perineum is performed with the patient in the supine hook-lying position. The examination should include a consideration of the position of the vulva, perineal body and clitoris and appearance of the vestibule, vagina and anal tissue for presence of infection, fissure or inflammation (Figure 6). Next, the sensory testing of the labia (genitofemoral and ilioinguinal nerve), vestibule (pudendal nerve branch to the clitoris and perineal branch), clitoris (pudendal nerve branch to the clitoris), vaginal opening (perineal branch), and rectal opening (pudendal nerve branch—levator ani and specific nerves to the anal sphincter) is conducted. Use of a cotton-tipped swab is recommended, with care being taken to avoid contamination from rectal to vaginal orifices.

Observations of pelvic floor movement for signs of incontinence or prolapse with respiration, straining (bearing down), and coughing are important for documenting functional ability and educating the patient on normal pelvic floor function. It is possible to detect the absence of pelvic floor descent with coughing (considered normal), although it is more typical to observe a descent even in those individuals without pain or dysfunction of the pelvic girdle.¹¹⁷ The presence of incontinence or organ tissue prolapse vs. simple pelvic floor descent would be considered a pathological finding.

The relationship between incontinence and pelvic pain is not directly correlated. Pelvic floor dysfunction, ie, hypotonus, hypertonus, weakness, or poor coordination can cause both problems but having any of the

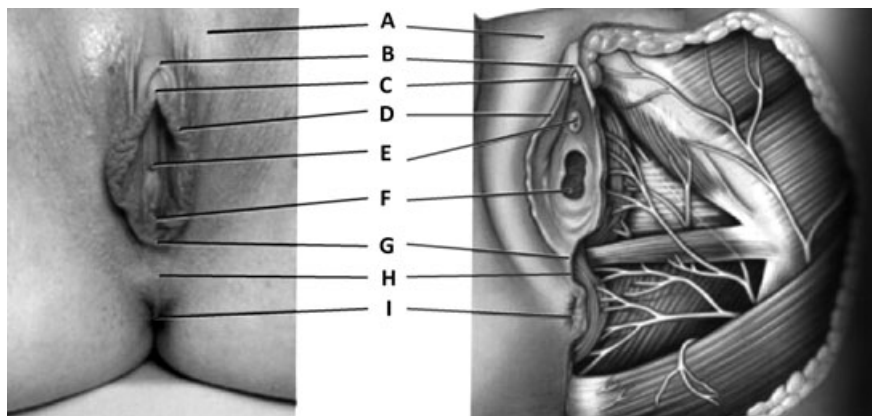


Figure 6. Pelvic region surface anatomy: external landmarks with corresponding structures. (A) labia majora, (B) prepuce of clitoris, (C) glans of clitoris, (D) labia minus, (E) external urethral orifice, (F) vaginal orifice, (G) posterior labial commissure, (H) perineal body, (I) anus.

dysfunctions does not necessarily mean both incontinence and pelvic pain will be present. However, a consideration of the presence of incontinence is noteworthy.

Specific muscle assessment is undertaken as the next step in the evaluation sequence (Figures 6 and 7). Analysis of the external pelvic floor muscles (ischio-cavernosus and bulbospongiosus, superficial transverse perineum, and perineal body) for spasm and tenderness, as well as documentation, is based on the location of the findings in the pelvic “clock,” where 12 o’clock is the mons pubis, urethra and clitoris in line with one another; Along the lines of 1 and 11 o’clock are the (L) and (R) ischiocavernosus muscles, respectively; 2 and 10 o’clock are the (L) and (R) bulbospongiosus muscles; 3 and 9 o’clock represent the (L) and (R) deep and superficial transverse perineum to each side of the vaginal opening; and 5 and 7 o’clock represent the (L) and (R) levator ani muscles on each side of the perineal body; and at 6 o’clock the clinician finds the perineal body.

Deeper intravaginal palpation up to the proximal interphalangeal joint of the examiner’s digit is used to assess for tone or tenderness in the levator ani group of muscles (iliococcygeus, coccygeus, puborectalis, and pubovaginalis), which surround the vaginal opening. The area of tenderness within this muscle group can be noted utilizing the same clock orientation.

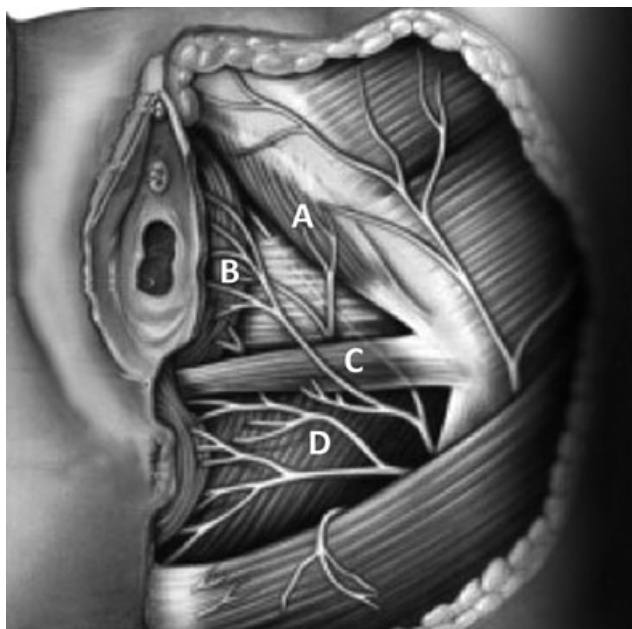


Figure 7. Palpable muscles of the pelvic floor: (A) ischiocavernosus, (B) bulbospongiosus, (C) superficial and deep transverse perinei, (D) levator ani.

Numerous authors have described assessment of pelvic floor contraction. Kegel¹¹⁸ described pelvic floor muscle contraction as a squeeze around the pelvic opening accompanied by an inward lift. Other procedures have been proposed to quantify muscle strength of the pelvic floor. Examination procedures include digital exam squeeze pressure using the PERF (pressure, endurance, repetitions, and fast flick) index, a modified Oxford scale as proposed by Laycock, or a Brink score, an objectified outcome from a vaginal perineometer, and surface EMG (SEMG).^{104,119–122} Each method measures a different aspect of pelvic floor muscle contraction.

The PERF index, as described by Laycock, can be performed during a clinical examination.¹²³ This can give the practitioner a measure of muscular performance, strength, endurance, as well as performance of fast and slow twitch fiber contributions. A perineometer is only able to measure the squeeze pressure, whereas the SEMG examination measures the number of motor units recruited and, as such, cannot be directly compared with the other two methods. Der Zalm, in their study evaluating pelvic floor function with various types of electrodes, found that various electrodes measure electrical activity in different structures based on the location of the recording portion of the electrode, as well as the shape and size of the electrode.¹²⁴ Clinicians who evaluate and treat the pelvic floor using SEMG electrode, whether external or internal, are encouraged to use the appropriate electrodes for each patient for recording PF function as well as assuring consistent placement.

A digital exam allows the clinician to appreciate not only the available strength via a squeeze but additionally to appreciate the amount of upward lift that serves as a component of the muscles’ strength.^{116,125} Digital examination squeeze assessment utilizing the PERF index is easy to perform but quantifying strength presents a challenge. Results from intra- and intertester reliability of vaginal palpation strength measurements have not been consistent, but vaginal palpation remains a key method of measuring contraction ability and correctness.

The digital pelvic floor PERF index assessment is completed with the patient in the supine hook-lying position. The patient is first instructed in the technique for performing a pelvic floor contraction, as it is necessary for a lifting and squeezing movement to occur.^{120,123} A single digit is inserted into the vagina, to a depth of up to 5 cm, the patient is then

asked to perform a maximal pelvic floor contraction as the clinician assesses the patient's degree of lift, muscular strength (0 to 5 modified Oxford scale) and contraction duration of up to 10 seconds. The contraction is graded using the modified Oxford scale (Table 1). The patient is then asked to repeat this contraction intensity and duration for as many repetitions as possible with the therapist documenting the grade of contraction (0 to 5), the duration of contraction and the number of sustained hold repetitions the patient is able to perform at the initial contraction intensity to a maximum of 10 repetitions. Finally, the patient is asked to perform a maximal contraction-relaxation as fast as possible and continue to repeat this sequence until the intensity of the contraction is decreased or to a maximum of 10 repetitions. This corresponds to the "F" in PERF, standing for fast flick repetitions.

Several investigators have found as much as 25% to 35% decrease in levator muscle strength after childbirth.⁶⁵ Anal sphincter trauma has been shown to occur in 1% to 5% of vaginal deliveries. The most important risk factors seem to be primiparity, large babies, and vaginal operative delivery. On ultrasound, however, structural alterations of the external anal sphincter are seen in up to 38% of vaginal deliveries. Disruption of the pelvic support structures has the potential of increasing mobility of the pelvic organs.^{65,78,126} A difference in muscle activation pattern has been shown when PFM contraction is performed correctly vs. a Valsalva maneuver. Thompson et al.¹²⁷ reported a significant activation of all the abdominal muscle and the chest wall during Valsalva vs. during PFM contraction. This caused an increase in the intra-abdominal pressure and increased pelvic floor descent in comparison to when contraction was correctly performed. This outcome has clinical consequences for incontinence and pelvic pain. The amount of pelvic stabilization is not necessarily improved with a Valsalva as compared with the correct PFM activation. Supportive dysfunction, such as with uterosacral ligament laxity causing pelvic or low back pain, may be exacerbated with a Valsalva.¹²⁸

Newer technologies continue to assist clinicians in evaluating pelvic floor function. Transabdominal ultrasound imaging (USI) has been used to assess function of the abdominal muscles, but transperineal USI appears to be a more reliable method to assess PFM contraction and appears to be more reliable in measuring Valsalva vs. transabdominal USI.¹²⁹ USI can allow

visualization of the contraction timing for the TrA and PFM. Furthermore, it can be utilized to train patients to perform a correct TrA activation with a simultaneous PFM activation.

Subsequently, pelvic support with cough or straining should be examined. For this testing sequence, the patient is asked to cough and to bear down. Palpation of the anterior and posterior vaginal wall is performed in order to analyze descent of the opposite wall into the vaginal opening. Awareness of cervix descent or uterine prolapse should be noted during this test. While these are important observations, the level of pelvic organ prolapse is only mildly correlated with level of incontinence and has not been studied in women with CPP. The clinician is interested in determining the function of the PFM structures, as dysfunction of the PFM and the impact on the alteration of postural support has been established.^{117,130}

Internal palpation of the obturator internus muscle can be performed with the patient in supine and the lower extremities in a figure-4 position (ankle on opposite knee). Palpation of the flexed hip side is made intravaginally in the direction of the obturator foramen. If tender points or fibrous bands are noted, these should be documented, as they can be signs of local pelvic floor dysfunction or a peripheral pain generator.^{107,111}

Finally, a pudendal nerve entrapment should be considered in cases of pelvic floor pain syndromes. Palpation for pudendal nerve symptom provocation can occur at the sacrospinous and sacrotuberous ligaments, as well as on the medial aspect of the pubic rami where it enters the fibro-osseous tunnel. To access the pudendal nerve, the patient is positioned in a hook lying position. The nerve may be palpated along the pudendal canal at the medial aspect of the ischial tuberosity and at its location as it passes through the space between the sacrotuberous and sacrospinous ligaments as well as intravaginal. If palpating intravaginal, the examiner directs the palpating digit toward the sacral spine. However, we cannot be certain as to whether the pudendal nerve or the levator ani nerve is the affected nerve with this palpation, due to the very close proximity of the two nerves.⁵⁸⁻⁶⁰ Thus, either nerve should be considered in response to a provocative palpation.

Coccygeal examination can be performed in the side lying position. External assessment can be completed to detect sensory changes and pain; however, assessment of position and function can only be completed with an

intrarectal palpation.²⁴ The normal sacrococcygeal angle averages 7° flexed from the midsacral axis in the sagittal plane, with considerable variations in normal angulation possible.¹³¹ If malposition is suspected, then a more specific assessment of the coccygeal position can be radiographically performed with the patient in both the sitting and standing postures. A 5° to 25° coccygeal position change between the two different postures is considered normal (Figures 8 and 9).^{24,132}

Contraction of the iliococcygeus, coccygeus and ischiococcygeus muscles will cause a flexion movement of the coccyx, as observed when an individual rises

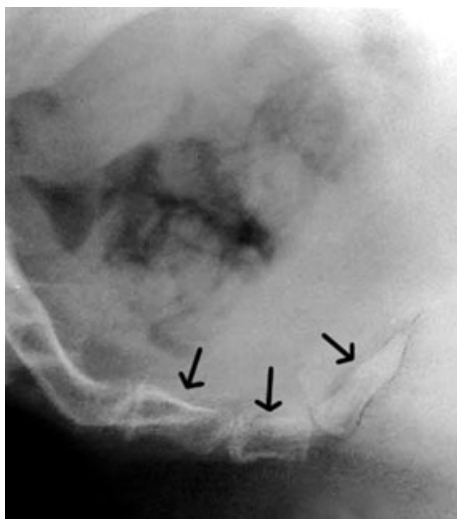


Figure 8. Angle of coccyx in relation to sacrum in sitting (arrows identify coccygeal segments). >25 degrees denotes hypermobility, potentially indicating a painful condition.

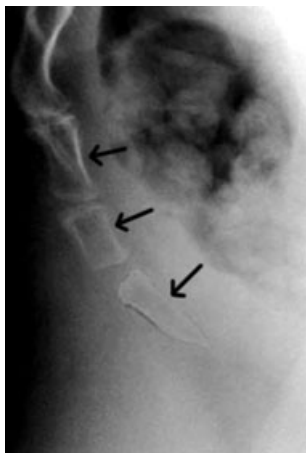

Figure 9. Angle of coccyx in relation to sacrum in standing (arrows identify coccygeal segments).

from sitting. If pain is provoked with muscular force and not with coccyx palpation, this indicates involvement of the levator ani muscles.¹³³ In this instance, the previously described complete pelvic floor examination may be indicated. For a patient with persistent pain and limited coccygeal movement on X-ray, coccygeal mobilization can be performed.¹³²

If the patient reports abdominal pain, concomitantly with a negative pelvic ring and upper lumbar screen, a specific examination of the abdominal wall is warranted. For a patient with prior abdominal surgery, there is a high index of suspicion for nerve entrapment, with the ilioinguinal nerve being most likely entrapped nerve. Each nerve presents with a unique region for symptom reference (Figure 10). The iliohypogastric nerve can be palpated along the mid-axillary line of the iliac crest down to the anterior superior iliac spine to the suprapubic area. The ilioinguinal nerve can be palpated along the inguinal ligament at a point 2 cm medial to the anterior superior iliac spine for the sensory branch to the groin and suprapubic area. Further palpation of the nerve is not possible. The genitofemoral nerve is not palpable in the abdominal region. Epineurial scarring that follows tension or blunt trauma can entrap the same nerves. Furthermore, the same nerves can be entrapped by scar tissue after any

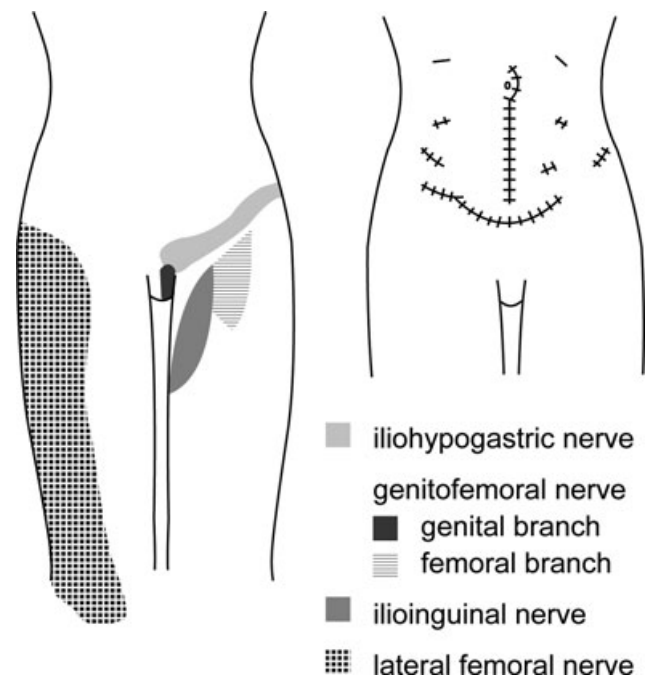


Figure 10. Symptom reference zones for the nerves of the anterior pelvis, along with visual depiction of various possible surgical incisions that could lead to nerve entrapment.

one of a number of surgical incisions. If the patient has no history of surgery, the cause is more likely viscerosomatic. Palpating the specific nerve exits should include palpation for paresthesias along the course of the nerve.

Motor Control Assessment

Movement strategies are important to note when the patient is focused on the strategy, as well as distracted from the same strategy. Thus, assessing movements of the pelvic girdle and lumbar spine can be accomplished during the initial history and clinical examination or may require more formal measures. A patient with pelvic pain may utilize a hyper extended spine posture with an anterior pelvic tilt when sitting, or may adopt a more relaxed posterior pelvic posture (sway posture).⁹⁴ Dynamic movements to assess motor control strategies can include general spinal movement, uni- or bipodal standing, and walking.^{48,94,134–136} Finally, the patient's ability to support the trunk with specific stabilizing muscle activity vs. global muscle activity can be a factor affecting painful conditions of the lumbar spine, sacroiliac joint and symphysis pubis and pelvic region.^{94,137,138} The goal of examination is to (1) assess the patient's ability to voluntarily activate selected local muscles (pelvic floor, TrA, Mf, diaphragm, and intercostalis thoracis) in a timely and efficient fashion, and (2) assess the presence of feedforward strategies in the relevant muscles, where each muscle produces a contraction prior to onset of trunk or extremity movement. This has been measured via diagnostic ultrasound applications, fine wire electromyography, surface electromyography, and palpation. However, to achieve clinical efficiency, the clinician is encouraged to use a qualitative palpation assessment of muscle recruitment.

Assessment of the local pelvic floor muscular system activation is subtle and can be difficult for the patient to identify. However, a well-trained clinician can facilitate this activation. Alteration in the onset and timing of feed-forward muscular response of the TrA has been identified in patients suffering from low back pain, sacroiliac joint pain, and postpartum pelvic pain.^{100,102,137,139} Similarly, altered motor control has been implicated in chronic groin pain conditions.^{1,138,140} Recent evidence demonstrated the ability to improve the temporal deficit with specific muscular training and should be incorporated into the treatment of patients demonstrating motor control deficits.^{96,141}

In addition, it is helpful to assess the mechanical integrity of tissues in the pelvic girdle, as the iliolumbar ligament and pelvic floor have been shown to enhance stability and force closure of the pelvis.^{31,142}

While definitive evidence is wanting, alteration of the normal elastic response of the pelvic floor to increase of intra-abdominal pressure may relate to CPP. In someone with chronic cough, the increased stress on an already weakened pelvic floor could lead to a nonrecoverable loss of pelvic floor sphincter function.⁴⁸ An understanding of the typical functions and dysfunctions of the pelvic floor, whether muscular damage, nerve injury or loss of fascial attachment in the initial precipitating event, must then be incorporated into assessment of causes for CPP.^{100,102}

Assessment of pelvic floor movement is best established with the use of USI followed by palpation.¹¹⁶ Evaluating the role pelvic floor musculoskeletal dysfunctions can play in the development of altered motor control patterns and is one goal of the nonoperative intervention.^{9,143} Correcting this motor control deficit may assist improving the local environment in a fashion sufficient for restoring function and minimizing pain; however, this has not been established specifically for pelvic pain conditions.

Examining for Sensitization

Nervous system sensitization will variably influence the CPP experience suffered by patients. When sensitized, the patient will complain of nonfocal pain, pain without a mechanical dysfunction, and a host of different biopsychosocial consequences, necessitating a team-based chronic pain intervention with a cognitive-behavioral management component.^{90,144} Signs of sensitization include somatic hyperalgesia and allodynia; as well as nausea, malaise, and visceral system hypersensitivity.¹⁴⁵ Often patients will present with mixed signs as the neurogenic inflammation that has persisted beyond the acute phase, producing neuroplastic changes in the peripheral and central nervous systems.¹⁴⁶

SUMMARY

Chronic pelvic pain is pain in the pelvic region that persists over a 6-month period, arising from gynecologic, urologic, gastrointestinal, and musculoskeletal pathologies/dysfunctions. The effective evaluation and management of this common, often expensive condition must be systematic and comprehensive. A careful

history, consideration for red flags, thorough clinical examination and tissue-specific pelvic examination should be utilized. A clinical examination schema that is based on the location of primary onset of symptoms (lumbosacral, coccygeal, sacroiliac, pelvic floor groin, or abdominal region) can be followed in order to treat the specific pain generator(s) manage tissue dysfunction.

REFERENCES

- Anderson K, Strickland SM, Warren R. Hip and groin injuries in athletes. *Am J Sports Med.* 2001;29:521–533.
- Ainsworth L, Budelier K, Clinesmith M, et al. Transcutaneous electrical nerve stimulation (TENS) reduces chronic hyperalgesia induced by muscle inflammation. *Pain.* 2006;120:182–187.
- Adams N, Poole H, Richardson C. Psychological approaches to chronic pain management: Part 1. *J Clin Nurs.* 2006;15:290–300.
- Garry R. Diagnosis of endometriosis and pelvic pain. *Fertil Steril.* 2006;86:1307–1309.
- Cheong Y, William Stones R. Chronic pelvic pain: aetiology and therapy. *Best Pract Res Clin Obstet Gynaecol.* 2006;20:695–711.
- Beard RW, Highman JH, Pearce S, Reginald PW. Diagnosis of pelvic varicosities in women with chronic pelvic pain. *Lancet.* 1984;2:946–949.
- Farquhar CM, Rogers V, Franks S, Pearce S, Wadsworth J, Beard RW. A randomized controlled trial of medroxyprogesterone acetate and psychotherapy for the treatment of pelvic congestion. *Br J Obstet Gynaecol.* 1989;96:1153–1162.
- Janicki TI. Chronic pelvic pain as a form of complex regional pain syndrome. *Clin Obstet Gynecol.* 2003;46:797–803.
- Gunter J. Chronic pelvic pain: an integrated approach to diagnosis and treatment. *Obstet Gynecol Surv.* 2003;58:615–623.
- Nader A, Candido KD. Pelvic pain. *Pain Pract.* 2001;1:187–196.
- Abrams P, Schalken JA. Etiology and management of pelvic pain syndrome. *Urology.* 2004;63:74.
- Frawley H, Bower W. Pelvic pain. In: Bo K, Berghmans B, Morkved S, VAn Kampen M, eds. *Evidence Based Physical Therapy for the Pelvic Floor: Bridging Science and Clinical Practice.* Edinburgh: Elsevier Ltd; 2007:249–265.
- Messelink B, Benson T, Berghmans B, et al. Standardization of terminology of pelvic floor muscle function and dysfunction: report from the pelvic floor clinical assessment group of the international continence society. *Neurourol Urodyn.* 2005;24:374–380.
- Clemons JL, Arya LA, Myers DL. Diagnosing interstitial cystitis in women with chronic pelvic pain. *Obstet Gynecol.* 2002;100:337–341.
- Wu EQ, Birnbaum H, Mareva M, et al. Interstitial cystitis: cost, treatment and co-morbidities in an employed population. *Pharmacoeconomics.* 2006;24:55–65.
- Peters KM, Carrico DJ. Frequency, urgency, and pelvic pain: treating the pelvic floor versus the epithelium. *Curr Urol Rep.* 2006;7:450–455.
- Sizer P, Phelps V, Thompsen K. Disorders of the sacroiliac joint. *Pain Pract.* 2002;2:17–34.
- Sizer P, Phelps V, Matthijs O. Pain generators of the lumbar spine. *Pain Pract.* 2001;1:255–273.
- Sizer PS Jr., Phelps V, Azevedo E. Disc related and non-disc related disorders of the thoracic spine. *Pain Pract.* 2001;1:136–149.
- Moore KL, Dalley AF. *Clinically Oriented Anatomy.* 4th ed. Baltimore, MD: Lippincott Williams & Wilkins; 1999.
- Forst SL, Wheeler MT, Fortin JD, Vilensky JA. The sacroiliac joint: anatomy, physiology and clinical significance. *Pain Physician.* 2006;9:61–67.
- Dar G, Hershkovitz I. Sacroiliac joint bridging: simple and reliable criteria for sexing the skeleton. *J Forensic Sci.* 2006;51:480–483.
- Cohen SP. Sacroiliac joint pain: a comprehensive review of anatomy, diagnosis, and treatment. *Anesth Analg.* 2005;101:1440–1453.
- Maigne JY, Tamalet B. Standardized radiologic protocol for the study of common coccygodynia and characteristics of the lesions observed in the sitting position: clinical elements differentiating luxation, hypermobility, and normal mobility. *Spine.* 1996;21:2588–2593.
- Wray CC, Easom S, Hoskinson J. Coccydynia: aetiology and treatment. *J Bone Joint Surg Br.* 1991;73:335–338.
- Balain B, Eisenstein SM, Alo GO, et al. Coccygectomy for coccydynia: case series and review of literature. *Spine.* 2006;31:E414–E420.
- Moseley GL, Hodges PW, Gandevia SC. Deep and superficial fibers of the lumbar multifidus muscle are differentially active during voluntary arm movements. *Spine (Phila Pa 1976).* 2002;27:E29–E36.
- Kavcic N, Grenier S, McGill SM. Quantifying tissue loads and spine stability while performing commonly prescribed low back stabilization exercises. *Spine (Phila Pa 1976).* 2004;29:2319–2329.
- Pel JJ, Spoor CW, Pool-Goudzwaard AL, Hoek van Dijke GA, Snijders CJ. Biomechanical analysis of reducing sacroiliac joint shear load by optimization of pelvic muscle and ligament forces. *Ann Biomed Eng.* 2008;36:415–424.
- Snijders CJ, Hermans PF, Kleinrensink GJ. Functional aspects of cross-legged sitting with special attention to piriformis muscles and sacroiliac joints. *Clin Biomech (Bristol, Avon).* 2006;21:116–121.
- Pool-Goudzwaard A, van Dijke GH, van Gorp M, Mulder P, Snijders C, Stoockart R. Contribution of pelvic floor muscles to stiffness of the pelvic ring. *Clin Biomech (Bristol, Avon).* 2004;19:564–571.

32. Woodman PJ, Graney DO. Anatomy and physiology of the female perineal body with relevance to obstetrical injury and repair. *Clin Anat*. 2002;15:321–334.
33. Shafik A, Sibai OE, Shafik AA, Shafik IA. A novel concept for the surgical anatomy of the perineal body. *Dis Colon Rectum*. 2007;50:2120–2125.
34. Shafik A, Ahmed I, Shafik AA, El-Ghamrawy TA, El-Sibai O. Surgical anatomy of the perineal muscles and their role in perineal disorders. *Anat Sci Int*. 2005;80:167–171.
35. Fritsch H, Lienemann A, Brenner E, Ludwikowski B. Clinical anatomy of the pelvic floor. *Adv Anat Embryol Cell Biol*. 2004;175:III–IX, 1–64.
36. Eilber KS, Rosenblum N, Gore J, Raz S, Rodriguez LV. Perineocele: symptom complex, description of anatomic defect, and surgical technique for repair. *Urology*. 2006;67:265–268.
37. Butrick CW. Pathophysiology of pelvic floor hyper-tonic disorders. *Obstet Gynecol Clin North Am*. 2009;36:699–705.
38. Mouritsen L. Classification and evaluation of prolapse. *Best Pract Res Clin Obstet Gynaecol*. 2005;19:895–911.
39. Kisli E, Kisli M, Agargun H, et al. Impaired function of the levator ani muscle in the grand multipara and great grand multipara. *Tohoku J Exp Med*. 2006;210:365–372.
40. Chen L, Ashton-Miller JA, Hsu Y, DeLancey JO. Interaction among apical support, levator ani impairment, and anterior vaginal wall prolapse. *Obstet Gynecol*. 2006;108:324–332.
41. Soderberg MW, Falconer C, Bystrom B, Malmstrom A, Ekman G. Young women with genital prolapse have a low collagen concentration. *Acta Obstet Gynecol Scand*. 2004;83:1193–1198.
42. Tinelli A, Malvasi A, Rahimi S, et al. Age-related pelvic floor modifications and prolapse risk factors in postmenopausal women. *Menopause*. 2010;17:204–212.
43. Petros PP, Skilling PM. Pelvic floor rehabilitation in the female according to the integral theory of female urinary incontinence: first report. *Eur J Obstet Gynecol Reprod Biol*. 2001;94:264–269.
44. Skilling PM, Petros P. Synergistic non-surgical management of pelvic floor dysfunction: second report. *Int Urogynecol J Pelvic Floor Dysfunct*. 2004;15:106–110 (discussion: 110).
45. Sapsford RR, Hodges PW. Contraction of the pelvic floor muscles during abdominal maneuvers. *Arch Phys Med Rehabil*. 2001;82:1081–1088.
46. Sapsford RR, Hodges PW, Richardson CA, Cooper DH, Markwell SJ, Jull GA. Co-activation of the abdominal and pelvic floor muscles during voluntary exercises. *Neuro-urol Urodyn*. 2001;20:31–42.
47. Sapsford R. Rehabilitation of pelvic floor muscles utilizing trunk stabilization. *Man Ther*. 2004;9:3–12.
48. Hodges PW, Sapsford R, Pengel LH. Postural and respiratory functions of the pelvic floor muscles. *Neuro-urol Urodyn*. 2007;26:362–371.
49. Mens JM, Damen L, Snijders CJ, Stam HJ. The mechanical effect of a pelvic belt in patients with pregnancy-related pelvic pain. *Clin Biomech (Bristol, Avon)*. 2006;21:122–127.
50. Mens JM, Vleeming A, Snijders CJ, Koes BW, Stam HJ. Validity of the active straight leg raise test for measuring disease severity in patients with posterior pelvic pain after pregnancy. *Spine*. 2002;27:196–200.
51. Mens JM, Vleeming A, Snijders CJ, Koes BW, Stam HJ. Reliability and validity of the active straight leg raise test in posterior pelvic pain since pregnancy. *Spine*. 2001;26:1167–1171.
52. Cramer G, Darby S. *Basic and Clinical Anatomy of the Spine, Spinal Cord, and ANS*. 2nd ed. Edinburgh: Elsevier Health Sciences; 2005.
53. Sizer P, Phelps V, Hay A, Azevedo E. Thoracic spine disorders, Part 1: history, inspection and clinical examination. *MD Consult* [serial online]. 2005;5:255–274.
54. Zhou Q, Fillingim RB, Riley JL III, Malarkey WB, Verne GN. Central and peripheral hypersensitivity in the irritable bowel syndrome. *Pain*. 2010;148:454–461.
55. McCrory P, Bell S. Nerve entrapment syndromes as a cause of pain in the hip, groin and buttock. *Sports Med*. 1999;27:261–274.
56. Perry CP. Peripheral neuropathies causing chronic pelvic pain. *J Am Assoc Gynecol Laparosc*. 2000;7:281–287.
57. Harvey G, Bell S. Obturator neuropathy: an anatomic perspective. *Clin Orthop Relat Res*. 1999;363:203–211.
58. Wallner C, Maas CP, Dabhoiwala NF, Lamers WH, DeRuiter MC. Innervation of the pelvic floor muscles: a reappraisal for the levator ani nerve. *Obstet Gynecol*. 2006;108:529–534.
59. Wallner C, van Wissen J, Maas CP, Dabhoiwala NF, DeRuiter MC, Lamers WH. The contribution of the levator ani nerve and the pudendal nerve to the innervation of the levator ani muscles; a study in human fetuses. *Eur Urol*. 2008;54:1136–1142.
60. Wallner C, Maas CP, Dabhoiwala NF, Lamers WH, DeRuiter MC. Evidence for the innervation of the puborectalis muscle by the levator ani nerve. *Neurogastroenterol Motil*. 2006;18:1121–1122.
61. Schraffordt SE, Tjandra JJ, Eizenberg N, Dwyer PL. Anatomy of the pudendal nerve and its terminal branches: a cadaver study. *ANZ J Surg*. 2004;74:23–26.
62. Vodusek DB. Neuroanatomy and neurophysiology of the pelvic floor muscles. In: Bo K, Berghmans B, Morkved S, Van Kampen M, eds. *Evidence Based Physical Therapy for the Pelvic Floor: Bridging Science and Clinical Practice*. Edinburgh: Elsevier Ltd; 2007:35–47.
63. Dietz HP, Lanzarone V. Levator trauma after vaginal delivery. *Obstet Gynecol*. 2005;106:707–712.

64. Dietz HP, Wilson PD. Childbirth and pelvic floor trauma. *Best Pract Res Clin Obstet Gynaecol.* 2005;19:913–924.
65. Dietz HP, Schierlitz L. Pelvic floor trauma in childbirth—myth or reality? *Aust N Z J Obstet Gynaecol.* 2005;45:3–11.
66. Dietz HP, Hyland G, Hay-Smith J. The assessment of levator trauma: a comparison between palpation and 4D pelvic floor ultrasound. *Neurourol Urodyn.* 2006;25:424–427.
67. Snooks SJ, Swash M, Henry MM, Setchell M. Risk factors in childbirth causing damage to the pelvic floor innervation. *Int J Colorectal Dis.* 1986;1:20–24.
68. Siddique SA, Gutman RE, Schon Ybarra MA, Rojas F, Handa VL. Relationship of the uterosacral ligament to the sacral plexus and to the pudendal nerve. *Int Urogynecol J Pelvic Floor Dysfunct.* 2006;17:642–645.
69. Mens JM, Vleeming A, Stoekart R, Stam HJ, Snijders CJ. Understanding peripartum pelvic pain: implications of a patient survey. *Spine.* 1996;21:1363–1369; discussion: 1369–1370.
70. Antolak SJ Jr, Hough DM, Pawlina W, Spinner RJ. Anatomical basis of chronic pelvic pain syndrome: the ischial spine and pudendal nerve entrapment. *Med Hypotheses.* 2002;59:349–353.
71. Wall PD, Melzack R, eds. *Textbook of Pain.* 4th ed. Edinburgh: Churchill Livingstone; 2000:5.
72. Bielefeldt K, Lamb K, Gebhart GF. Convergence of sensory pathways in the development of somatic and visceral hypersensitivity. *Am J Physiol Gastrointest Liver Physiol.* 2006;291:G658–G665.
73. Travell J, Simons DG. *Myofascial Pain and Dysfunction: The Trigger Point Manual.* Vol. 2. Philadelphia, PA: Lippincott Williams & Wilkins; 1993.
74. Honjo H, Kamoi K, Naya Y, et al. Effects of acupuncture for chronic pelvic pain syndrome with intrapelvic venous congestion: preliminary results. *Int J Urol.* 2004;11:607–612.
75. Barber MD, Bremer RE, Thor KB, Dolber PC, Kuehl TJ, Coates KW. Innervation of the female levator ani muscles. *Am J Obstet Gynecol.* 2002;187:64–71.
76. Jundt K, Kiening M, Fischer P, et al. Is the histomorphological concept of the female pelvic floor and its changes due to age and vaginal delivery correct? *Neurourol Urodyn.* 2005;24:44–50.
77. Kokcu A, Yanik F, Cetinkaya M, Alper T, Kandemir B, Malatyalioglu E. Histopathological evaluation of the connective tissue of the vaginal fascia and the uterine ligaments in women with and without pelvic relaxation. *Arch Gynecol Obstet.* 2002;266:75–78.
78. Leyendecker JR, Gorengaut V, Brown JJ. MR imaging of maternal diseases of the abdomen and pelvis during pregnancy and the immediate postpartum period. *Radiographics.* 2004;24:1301–1316.
79. Makinen J, Soderstrom KO, Kiilholma P, Hirvonen T. Histological changes in the vaginal connective tissue of patients with and without uterine prolapse. *Arch Gynecol.* 1986;239:17–20.
80. Silva WA, Karram MM. Anatomy and physiology of the pelvic floor. *Minerva Ginecol.* 2004;56:283–302.
81. Paulson JD, Delgado M. Chronic pelvic pain: the occurrence of interstitial cystitis in a gynecological population. *JLS.* 2005;9:426–430.
82. Mathias SD, Kuppermann M, Liberman RF, Lipschutz RC, Steege JF. Chronic pelvic pain: prevalence, health-related quality of life, and economic correlates. *Obstet Gynecol.* 1996;87:321–327.
83. Tu FF, As-Sanie S, Steege JF. Musculoskeletal causes of chronic pelvic pain: a systematic review of diagnosis: part I. *Obstet Gynecol Surv.* 2005;60:379–385.
84. Barber MD, Kuchibhatla MN, Pieper CF, Bump RC. Psychometric evaluation of 2 comprehensive condition-specific quality of life instruments for women with pelvic floor disorders. *Am J Obstet Gynecol.* 2001;185:1388–1395.
85. Teng J, Mekhail N. Neuropathic pain: mechanisms and treatment options. *Pain Pract.* 2003;3:8–21.
86. Craig AD. Pain mechanisms: labeled lines versus convergence in central processing. *Annu Rev Neurosci.* 2003;26:1–30.
87. Passero C. Pathophysiology of neuropathic pain. *Pain Manag Nurs.* 2004;5:3–8.
88. Heitkemper M, Jarrett M. Overlapping conditions in women with irritable bowel syndrome. *Urol Nurs.* 2005;25:25–30; quiz: 31.
89. Baker K. Recent advances in the neurophysiology of chronic pain. *Emerg Med Australas.* 2005;17:65–72.
90. Turk DC. Cognitive-behavioral approach to the treatment of chronic pain clients. *Reg Anesth Pain Med.* 2003;28:573–579.
91. Gallagher RM. Rational integration of pharmacologic, behavioral, and rehabilitation strategies in the treatment of chronic pain. *Am J Phys Med Rehabil.* 2005;84:S64–S76.
92. Heim LJ. Evaluation and differential diagnosis of dyspareunia. *Am Fam Physician.* 2001;63:1535–1544.
93. Siddall PJ, Cousins MJ. Persistent pain as a disease entity: implications for clinical management. *Anesth Analg.* 2004;99:510–520 (table of contents).
94. O'Sullivan PB, Beales DJ. Diagnosis and classification of pelvic girdle pain disorders, Part 1: a mechanism based approach within a biopsychosocial framework. *Man Ther.* 2007;12:86–97.
95. O'Sullivan PB, Beales DJ. Diagnosis and classification of pelvic girdle pain disorders, Part 2: illustration of the utility of a classification system via case studies. *Man Ther.* 2007;12:e1–e12.
96. O'Sullivan PB, Beales DJ. Changes in pelvic floor and diaphragm kinematics and respiratory patterns in subjects with sacroiliac joint pain following a motor learning intervention: a case series. *Man Ther.* 2007;12:209–218.
97. Laslett M. Pain provocation tests for diagnosis of sacroiliac joint pain. *Aust J Physiother.* 2006;52:229.

98. Laslett M, Aprill CN, McDonald B. Provocation sacroiliac joint tests have validity in the diagnosis of sacroiliac joint pain. *Arch Phys Med Rehabil*. 2006;87:874; author reply: 874–875.
99. Laslett M, Aprill CN, McDonald B, Young SB. Diagnosis of sacroiliac joint pain: validity of individual provocation tests and composites of tests. *Man Ther*. 2005;10:207–218.
100. Mens JM, Vleeming A, Snijders CJ, Stam HJ, Ginai AZ. The active straight leg raising test and mobility of the pelvic joints. *Eur Spine J*. 1999;8:468–473.
101. Mens JM, Vleeming A, Snijders CJ, Ronchetti I, Ginai AZ, Stam HJ. Responsiveness of outcome measurements in rehabilitation of patients with posterior pelvic pain since pregnancy. *Spine*. 2002;27:1110–1115.
102. Hungerford B, Gilleard W, Hodges P. Evidence of altered lumbopelvic muscle recruitment in the presence of sacroiliac joint pain. *Spine*. 2003;28:1593–1600.
103. Borello-France DF, Handa VL, Brown MB, et al. Pelvic-floor muscle function in women with pelvic organ prolapse. *Phys Ther*. 2007;87:399–407.
104. Bo K, Sherburn M. Evaluation of female pelvic-floor muscle function and strength. *Phys Ther*. 2005;85:269–282.
105. Majlesi J, Togay H, Unalan H, Toprak S. The sensitivity and specificity of the slump and the straight leg raising tests in patients with lumbar disc herniation. *J Clin Rheumatol*. 2008;14:87–91.
106. Sizer PS, Phelps VA, Brismée JM, VanParidon D, Matthijs O. *Diagnosis Specific Orthopedic Management of the Hip*. Minneapolis, MN: OPTP; 2007.
107. Weiss JM. Pelvic floor myofascial trigger points: manual therapy for interstitial cystitis and the urgency-frequency syndrome. *J Urol*. 2001;166:2226–2231.
108. Oyama IA, Rejba A, Lukban JC, et al. Modified Thiele massage as therapeutic intervention for female patients with interstitial cystitis and high-tone pelvic floor dysfunction. *Urology*. 2004;64:862–865.
109. FitzGerald MP, Kotarinos R. Rehabilitation of the short pelvic floor. I: background and patient evaluation. *Int Urogynecol J Pelvic Floor Dysfunct*. 2003;14:261–268.
110. FitzGerald MP, Kotarinos R. Rehabilitation of the short pelvic floor. II: treatment of the patient with the short pelvic floor. *Int Urogynecol J Pelvic Floor Dysfunct*. 2003;14:269–275 (discussion: 275).
111. Dommerholt J, Bron C, Franssen J. Myofascial trigger points: an evidence-informed review. *J Man Manip Ther*. 2006;14:203–221.
112. Moseley GL, Nicholas MK, Hodges PW. Pain differs from non-painful attention demanding or stressful tasks in its effect on postural control patterns of trunk muscles. *Exp Brain Res*. 2004;156:64–71.
113. Moseley GL, Nicholas MK, Hodges PW. Does anticipation of back pain predispose to back trouble? *Brain*. 2004;127:2339–2347.
114. Comiter CV. Sacral neuromodulation for the symptomatic treatment of refractory interstitial cystitis: a prospective study. *J Urol*. 2003;169:1369–1373.
115. Ramsden CE, McDaniel MC, Harmon RL, Renney KM, Faure A. Pudendal nerve entrapment as source of intractable perineal pain. *Am J Phys Med Rehabil*. 2003;82:479–484.
116. Bo K, Finckenhagen HB. Is there any difference in measurement of pelvic floor muscle strength in supine and standing position? *Acta Obstet Gynecol Scand*. 2003;82:1120–1124.
117. Trowbridge ER, Wei JT, Fenner DE, Ashton-Miller JA, Delancey JO. Effects of aging on lower urinary tract and pelvic floor function in nulliparous women. *Obstet Gynecol*. 2007;109:715–720.
118. Kegel AH. Progressive resistance exercise in the functional restoration of the perineal muscles. *Am J Obstet Gynecol*. 1948;56:238–249.
119. Laycock J. Pelvic muscle exercises: physiotherapy for the pelvic floor. *Urol Nurs*. 1994;14:136–140.
120. Bo K, Finckenhagen HB. Vaginal palpation of pelvic floor muscle strength: inter-test reproducibility and comparison between palpation and vaginal squeeze pressure. *Acta Obstet Gynecol Scand*. 2001;80:883–887.
121. Hundley AF, Wu JM, Visco AG. A comparison of perineometer to brink score for assessment of pelvic floor muscle strength. *Am J Obstet Gynecol*. 2005;192:1583–1591.
122. Bo K, Raastad R, Finckenhagen HB. Does the size of the vaginal probe affect measurement of pelvic floor muscle strength? *Acta Obstet Gynecol Scand*. 2005;84:129–133.
123. Laycock J, Jerwood D. Pelvic floor assessment: the P.E.R.F.E.C.T. scheme. *Physiotherapy*. 2001;87:631–642.
124. der Zalm PJ, Pelger RC, van Heeswijk-Faase IC, et al. Placement of probes in electrostimulation and biofeedback training in pelvic floor dysfunction. *Acta Obstet Gynecol Scand*. 2006;85:850–855.
125. Shelly B, Dunbar A. Palpation and assessment of the pelvic floor muscles using depth and positional measurements. *J Sect Womens Health*. 2004;28:19–24.
126. Bump RC, Norton PA. Epidemiology and natural history of pelvic floor dysfunction. *Obstet Gynecol Clin North Am*. 1998;25:723–746.
127. Thompson JA, O'Sullivan PB, Briffa NK, Neumann P. Altered muscle activation patterns in symptomatic women during pelvic floor muscle contraction and valsalva manoeuvre. *Neurourol Urodyn*. 2006;25:268–276.
128. Thompson JA, O'Sullivan PB, Briffa NK, Neumann P. Differences in muscle activation patterns during pelvic floor muscle contraction and valsalva maneuver. *Neurourol Urodyn*. 2006;25:148–155.
129. Thompson JA, O'Sullivan PB, Briffa K, Neumann P, Court S. Assessment of pelvic floor movement using transabdominal and transperineal ultrasound. *Int Urogynecol J Pelvic Floor Dysfunct*. 2005;16:285–292.

130. Shagam JY. Pelvic organ prolapse. *Radiol Technol.* 2006;77:389–400; quiz: 401–403.
131. Maigne JY, Lagauche D, Doursounian L. Instability of the coccyx in coccydynia. *J Bone Joint Surg Br.* 2000;82:1038–1041.
132. Maigne JY, Chatellier G, Faou ML, Archambeau M. The treatment of chronic coccydynia with intrarectal manipulation: a randomized controlled study. *Spine.* 2006;31:E621–E627.
133. De Andres J, Chaves S. Coccygodynia: a proposal for an algorithm for treatment. *J Pain.* 2003;4:257–266.
134. Smith MD, Coppieters MW, Hodges PW. Postural response of the pelvic floor and abdominal muscles in women with and without incontinence. *NeuroUrol Urodyn.* 2007;26:377–385.
135. Smith MD, Coppieters MW, Hodges PW. Postural activity of the pelvic floor muscles is delayed during rapid arm movements in women with stress urinary incontinence. *Int Urogynecol J Pelvic Floor Dysfunct.* 2007;18:901–911.
136. Smith MD, Coppieters MW, Hodges PW. Is balance different in women with and without stress urinary incontinence? *NeuroUrol Urodyn.* 2008;27:71–78.
137. Hodges PW, Richardson CA. Inefficient muscular stabilization of the lumbar spine associated with low back pain. A motor control evaluation of transversus abdominis. *Spine.* 1996;21:2640–2650.
138. Cowan SM, Schache AG, Brukner P, et al. Delayed onset of transverse abdominus in long-standing groin pain. *Med Sci Sports Exerc.* 2003;26:1–30.
139. O’Sullivan PB, Grahamslaw KM, Kendell M, Lapenskie SC, Moller NE, Richards KV. The effect of different standing and sitting postures on trunk muscle activity in a pain-free population. *Spine.* 2002;27:1238–1244.
140. Meyers WC, Foley DP, Garrett WE, Lohnes JH, Mandlebaum BR. Management of severe lower abdominal or inguinal pain in high-performance athletes. PAIN (performing athletes with abdominal or inguinal neuromuscular pain study group). *Am J Sports Med.* 2000;28:2–8.
141. Stuge B, Laerum E, Kirkesola G, Vollestad N. The efficacy of a treatment program focusing on specific stabilizing exercises for pelvic girdle pain after pregnancy: a randomized controlled trial. *Spine.* 2004;29:351–359.
142. Pel JJ, Spoor CW, Goossens RH, Pool-Goudzwaard AL. Biomechanical model study of pelvic belt influence on muscle and ligament forces. *J Biomech.* 2008;41:1878–1884.
143. Zelle BA, Gruen GS, Brown S, George S. Sacroiliac joint dysfunction: evaluation and management. *Clin J Pain.* 2005;21:446–455.
144. Stanos SP, McLean J, Radar L. Physical medicine rehabilitation approach to pain. *Med Clin North Am.* 2007;91:57–95.
145. Butrick CW. Interstitial cystitis and chronic pelvic pain: new insights in neuropathology, diagnosis, and treatment. *Clin Obstet Gynecol.* 2003;46:811–823.
146. Cervero F, Laird JM. Understanding the signaling and transmission of visceral nociceptive events. *J Neurobiol.* 2004;61:45–54.

SUPPORTING INFORMATION

Additional Supporting Information may be found in the online version of this article:

Appendix S1 Clinical examination schema for chronic pelvic pain.

Appendix S2 Chronic pelvic pain: differential diagnostic possibilities by pain location.

Please note: Wiley–Blackwell are not responsible for the content or functionality of any supporting information supplied by the authors. Any queries (other than missing material) should be directed to the corresponding author for the article.