

# Lateral Epicondylitis of the Elbow

Rick Tosti, MD,<sup>a</sup> John Jennings, BS,<sup>b</sup> J. Milo Sowards, MD<sup>a</sup>

<sup>a</sup>Department of Orthopaedic Surgery and Sports Medicine, Temple University School of Medicine, Philadelphia, Pa; <sup>b</sup>Temple University School of Medicine, Philadelphia, Pa.

## ABSTRACT

Lateral epicondylitis, or “tennis elbow,” is a common musculotendinous degenerative disorder of the extensor origin at the lateral humeral epicondyle. Repetitive occupational or athletic activities involving wrist extension and supination are thought to be causative. The typical symptoms include lateral elbow pain, pain with wrist extension, and weakened grip strength. The diagnosis is made clinically through history and physical examination; however, a thorough understanding of the differential diagnosis is imperative to prevent unnecessary testing and therapies. Most patients improve with nonoperative measures, such as activity modification, physical therapy, and injections. A small percentage of patients will require surgical release of the extensor carpi radialis brevis tendon. Common methods of release may be performed via percutaneous, arthroscopic, or open approaches.

© 2013 Elsevier Inc. All rights reserved. • *The American Journal of Medicine* (2013) 126, 357.e1-357.e6

**KEYWORDS:** Lateral epicondylitis; Tennis elbow

The term “tennis elbow” has persisted since its initial description by Morris<sup>1</sup> as “lawn tennis arm” in 1883. Despite the fact that less than 10% of patients with this syndrome are actually tennis players, it is estimated that 50% of those who play tennis will experience some degree of lateral elbow pain in their lifetimes.<sup>2,3</sup> Furthermore, the incidence of lateral epicondylitis is significantly higher in novice tennis players and those who use a 1-handed backhand stroke, which is likely a result of poor technique.<sup>4,5</sup>

The prevalence of lateral epicondylitis in the general population has been reported to range from 1% to 3% in adults, with men and women being affected equally.<sup>4,6,7</sup> Lateral epicondylitis is most prevalent in the fifth decade of life, with peak incidence occurring between the ages of 45 and 54 years; those with manually intensive occupations or those who use vibratory tools may have an increased risk.<sup>7,8</sup>

**Funding:** None.

**Conflict of Interest:** None.

**Authorship:** All authors had access to the data and played a role in writing this manuscript.

Requests for reprints should be addressed to Rick Tosti, MD, Temple University School of Medicine, Orthopaedic Surgery and Sports Medicine, 3401 N. Broad St, Philadelphia, PA 19140.

E-mail address: [rtosti@temple.edu](mailto:rtosti@temple.edu)

## ANATOMY

The lateral elbow is composed of bony and ligamentous structures that stabilize the joint and serve as an origin for the musculotendinous attachments of the dorsal forearm. The common extensor origin consists of 5 muscles: the extensor carpi radialis longus and brevis, extensor digitorum communis, extensor digiti minimi, and extensor carpi ulnaris. This complex originates chiefly from the lateral humeral epicondyle; however, it should be noted that the extensor carpi radialis brevis takes its origin from multiple points, including deep structures such as the lateral collateral ligament, annular ligament, and intermuscular septum. Distally, the extensor carpi radialis brevis inserts on the base of the third metacarpal distinguishing it as the central wrist extensor.

## PATHOMECHANICS

Clinical studies have shown that pain genesis about the lateral elbow occurs as a result of dynamic stabilization of the wrist and repetitive loading of the tendons, and muscle activity during tennis play is often used as a model for the pathomechanics. Electromyographic studies of groundstrokes in tennis players have shown the greatest muscle activity in the wrist extensors in general and the extensor carpi radialis brevis in particular.<sup>9</sup> Moreover, these tendons experience the most excessive loading at the lateral epicondyle during the 1-handed backhand stroke.<sup>10</sup> In addition, the

position of wrist supination and elbow extension during backhand strokes generates increased contact pressures between the extensor carpi radialis brevis and capitellum, which may further contribute to the degenerative process.<sup>11,12</sup> In general practice, activities or occupations that involve repetitive wrist extension and supination generate analogous pathomechanics.<sup>6</sup>

## **PATHOLOGY**

Initially, the pathologic process of lateral epicondylitis was described as inflammatory; however, the current consensus is that micro-trauma initiates a degenerative process.<sup>4,6,13,14</sup> In their classic report, Nirschl and Pettrone<sup>15</sup> described gross examination of the extensor carpi radialis brevis in patients with tennis elbow as “grayish, immature scar tissue, which appears shiny, edematous, and friable.” Histologic studies of these specimens were described as having “angiofibroblastic hyperplasia,” in which the collagen microstructure was invaded by fibroblasts and vascular granulation.<sup>15</sup> Of note, this description is consistent with that of normal tendons after corticosteroid injections.<sup>16</sup> Currently, no studies to our knowledge have observed histologic changes in subjects who have not received at least 1 prior steroid injection before surgery, and inflammatory cells have not been observed in histologic specimens obtained from surgery.<sup>2</sup>

## **DIAGNOSIS**

The classic description of lateral epicondylitis is tenderness over the common extensor origin just anterior and distal to the lateral humeral epicondyle. The pain is typically of insidious onset and may coincide with recent changes in occupational or sporting activities. Patients often report a unique discomfort with shaking hands, shaving, lifting luggage or groceries with an extended elbow, or raising a coffee mug. Physical examination on an extended elbow reveals reproduction of symptoms with resisted middle finger and wrist extension, and examination on a flexed elbow will reproduce pain if the degenerative process is more severe. Generally, range of motion at the wrist and elbow demonstrates a full range of motion. Grip strength may be diminished secondary to pain.<sup>2</sup> The “chair test,” described by Gardner<sup>17</sup> as the “most important clinical finding,” elicits lateral elbow pain on lifting a chair with a pronated hand (**Figure 1**). Anteroposterior and lateral radiographs are usually normal or may show mild soft tissue calcifications; however, it is generally routine in an orthopedic practice to order these films to exclude other pathologies. Magnetic resonance imaging is usually unnecessary and will often show increased signal

intensity near the common extensor origin and adjacent soft tissues. However, magnetic resonance imaging may be useful if concomitant intra-articular pathology is suspected.

Alternative diagnoses to be considered when a patient presents with atraumatic lateral elbow pain may include radicular cervical spine disease, radial nerve compression, intrarticular loose bodies, and chondral lesions. Less commonly, tumors, avascular necrosis, and osteochondritis dissecans of the capitellum may be considered. **Table 1** is a reference for discerning differences among possible causes of lateral elbow pain.

## **NONOPERATIVE MANAGEMENT**

The mainstay of treatment for lateral epicondylitis is nonoperative, and reports describe improvement without surgery in up to 95% of cases.<sup>18</sup> Physical therapy, activity modification, nonsteroidal anti-inflammatory drugs, and injections are the primary nonoperative mo-

dalities and will be discussed separately.

## **Physical Therapy and Activity Modification**

Multiple physiotherapy methods have been described. Stasinopoulos and Johnson<sup>19</sup> advocated “deep transverse friction” and Mill’s manipulation, which is essentially a deep tissue massage over the point of maximal tenderness combined with stretching maneuvers. Calfee et al<sup>6</sup> suggested a course of forearm strength training, stretching, and hot-cold modalities. The recent addition of eccentric muscle training has demonstrated promising results with significant improvements in both pain and strength.<sup>20</sup>

Counterforce bracing theoretically inhibits full muscular expansion and creates a more distal origin, thus decreasing the forces on the bony origin of the common extensor tendon. Studies using indwelling electromyography demonstrated significantly reduced extensor muscle activity during maximum isometric contraction while using a counterforce brace.<sup>21</sup> Occasionally, these braces may be prescribed as an adjunctive therapy, but their efficacy in reducing symptoms alone is limited.

Tennis elbow seems to be more common in amateur players as opposed to elite players, which suggests that swinging technique may be a causative factor.<sup>4,22</sup> Traditional teaching aims to modify the forehand stroke by retraining the player to hit the ball in front of the body when the elbow and wrist are extended; thus, the upper arm and core muscles provide a greater contribution to the swing. A 2-handed backhand stroke additionally diffuses the tension between both upper extremities and partially relieves the

## **CLINICAL SIGNIFICANCE**

- Lateral epicondylitis is a common cause of lateral elbow pain caused by overuse of the wrist and usually affects adults in the fifth and sixth decades of life.
- Nonoperative measures are often successful and consist of activity modification, bracing, physical therapy, and injections.
- Refractory cases of lateral elbow pain should be evaluated for alternative diagnoses and may be referred to an orthopedic surgeon for operative release of the extensor carpi radialis brevis tendon.



**Figure 1** The chair test is positive when lateral elbow pain is elicited during the lifting of a chair with a pronated hand.

dominant wrist. In addition to biokinetic alterations, equipment adjustments also may reduce symptoms; racquets that are lighter, that are less tightly strung, or that have more strings per unit area transmit milder loads to the elbow. Manufacturing companies cite Nirschl and Pettrone's<sup>15</sup> recommendation of proper grip size, which states that the optimal size of the circumference of the grip is estimated by the length from the proximal palmar crease to the tip of the ring finger along the radial border; although the media often attributes suboptimal grip size to the development of tennis elbow, a recent study<sup>23</sup> showed that electromyographic activity of the wrist extensors muscles is not affected by variations within a ¼ inch of Nirschl and Pettrone's<sup>15</sup> estimate.

Other modalities in physical therapy are being studied, albeit with limited frequency and long-term follow-up data. Extracorporeal shock-wave therapy, laser light therapy, acupuncture, electromagnetic field therapy, low-intensity ultrasound, and iontophoresis with dexamethasone would be among those physical therapy modalities in current practice; however, at present no evidence supports their routine use.

## Nonsteroidal Anti-inflammatory Drugs

A 10- to 14-day course of oral anti-inflammatory medication may be recommended if the patient has no medical contraindication.<sup>24</sup> Although nonsteroidal anti-inflammatory drugs are commonly prescribed, their use in lateral epicondylitis is controversial and has not been supported by high-quality studies.<sup>25</sup> Although inflammatory cells have not been observed in microscopic evaluations of extensor carpi radialis brevis tendons, nonsteroidal anti-inflammatory drugs may relieve pain by an analgesic effect or by reducing local inflammation in the surrounding synovial, muscle, or connective tissue.<sup>6</sup> A recent multicenter, double-blinded, randomized comparison of diclofenac versus placebo in lateral epicondylitis showed a significant reduction in subjective pain scores at 4 weeks but no difference in functional score or grip strength; abdominal pain was more common in the treatment group, and the authors' conclusion did not support the routine prescription of diclofenac based on the risk/benefit profile.<sup>26</sup>

## Injections

Various injectables are used in the treatment of lateral epicondylitis. The most common compounds are corticosteroids; however, a recent increase in the frequency of autologous whole blood, platelet-rich plasma, and botulinum toxin has been observed. The technique for tennis elbow injection begins with entry of a needle 1 cm distal and 1 cm anterior to the lateral epicondyle as shown in **Figure 2**. Botulinum toxin is injected into the muscle approximately 5 cm distal to the point of maximal tenderness.<sup>27</sup>

Comparative studies involving corticosteroids versus placebo or physiotherapy seem to favor the use of corticosteroid injections only in the short term.<sup>6,11,24,28</sup> Bisset et al<sup>29</sup> compared observation against both physiotherapy and corticosteroid injections over a 1-year period. They found that corticosteroids improved symptoms at 6 weeks but actually had higher rates of recurrence at 1 year. At present, no corticosteroid preparation has been shown to be superior,<sup>25,28</sup> and reported side effects of percutaneous administration include skin depigmentation, fat atrophy, decreased collagen production, transient elevation of blood glucose in diabetic patients, and common extensor tendon rupture, which may occur with frequently administered or inappropriately placed injections.<sup>6</sup>

Platelet-rich plasma entered popular media in 2009 after its use in elite athletes before Super Bowl XLIII. Since then, the attention of platelet-rich plasma in musculoskeletal disorders (including lateral epicondylitis) has increased dramatically. In a 2-year level I study of chronic lateral epicondylitis by Gosens et al,<sup>30</sup> platelet-rich plasma injections showed significantly improved clinical scores when compared with corticosteroid injections. A criticism of the study was a lack of control subjects. Another level I study by Thanasis et al<sup>31</sup> showed no difference in clinical scores between platelet-rich plasma and whole blood injections at 6 months. Other studies have compared autologous blood,



**Table 1** Differential Diagnosis of Lateral Elbow Pain

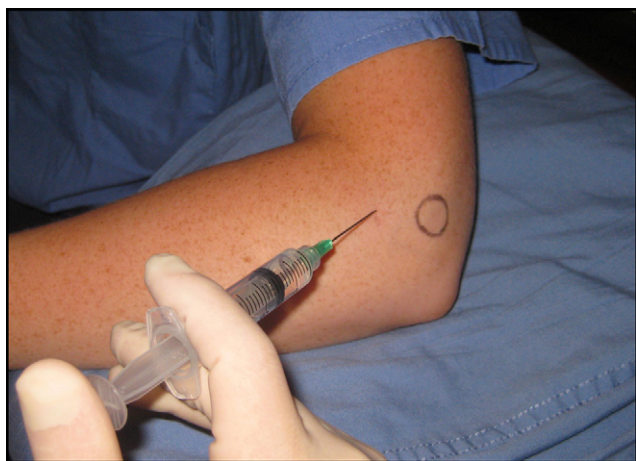
Pathology	History	Physical Examination	Imaging
Cervical spondylosis	Radicular pain into the elbow Neck pain	Symptoms with spine compression/ extension	X-ray + MRI of c-spine
Radial tunnel syndrome	Insidious onset of lateral elbow pain	Pain 2-4 cm distal to epicondyle	EMG + NCS*
PIN compression	Insidious onset of lateral elbow pain and weakness	Weakness of wrist and finger extensors	EMG + NCS
Intra-articular loose bodies	Trauma Weight lifting	Clicking or limitation of range of motion	X-ray of elbow
Chondral lesions	Trauma Weight lifting	Clicking or limitation of range of motion	MRI of elbow
Tumors	Prior malignancy, night pain, constitutional symptoms	Palpable mass	X-ray + MRI of elbow
Avascular necrosis	Sickle cell anemia, alcohol abuse, HIV, corticosteroids	Joint effusion, mechanical symptoms	X-ray + MRI of elbow
Osteochondritis dessicans	Adolescent patients, gymnasts, throwers	Joint effusion, mechanical symptoms	X-ray of the elbow

EMG = electromyography; MRI = magnetic resonance imaging; NCS = nerve conduction studies; PIN = posterior interosseous nerve.

\*EMG + NCS are rarely diagnostic in radial tunnel syndrome, and it is typically a clinical diagnosis.

corticosteroid, and saline injections and found no statistical difference between groups at 2 and 6 months.<sup>32</sup> Currently, the optimal use of biologic injectables for lateral epicondylitis is not yet defined; the optimal timing, concentration, and number of injections are not known, and the cost can be prohibitive for many patients.

Although many of the clinical studies question the efficacy of individual nonoperative strategies, it should be noted that nonoperative management is successful in more than 90% of cases.<sup>33</sup> In the clinical setting, it is reasonable to attempt a combination of these approaches, and as a result, most patients experience improvement or resolution of their symptoms without the need for surgery.



**Figure 2** Lateral epicondylitis injection is performed with the needle entering the skin at a 45-degree angle and entering 1 cm anterior and 1 cm distal to the lateral epicondyle (circled in black); this usually corresponds to the area of maximal tenderness. The needle is advanced to the periosteum and redirected multiple times to spread the solution along the tendon origin and stimulate bleeding.

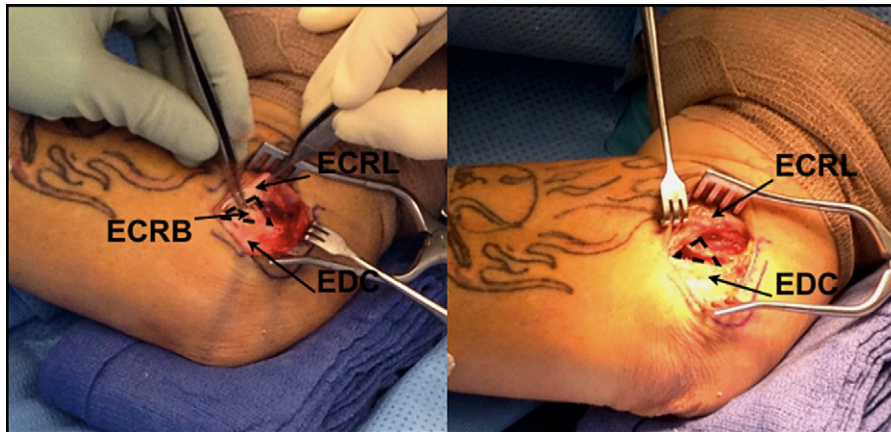
## OPERATIVE MANAGEMENT

Failure of nonoperative therapy represents the most common indication for surgical treatment; however, before surgery is considered, other causes of lateral elbow pain should be excluded. As much as 8% of patients may qualify as surgical candidates, which in most cases signifies persistent symptoms after 6 to 12 months of nonsurgical therapy.<sup>33</sup> Many methods have been described, but 3 common approaches are percutaneous, arthroscopic, and open.

Percutaneous release may be performed in the office or operating room. Initially, a 1-cm incision over the mid-point of the lateral epicondyle is made revealing the common extensor origin, which is visualized and divided.<sup>33,34</sup> The extensor carpi radialis brevis is not repaired, nor is any pathologic tissue removed; however, the incision is small and recovery time is short.

Generally, arthroscopic release is indicated in patients with concomitant intra-articular pathology, such as loose bodies, chondral flaps, or arthritis. Visualization is achieved through a medial portal, and the lateral capsule and extensor carpi radialis brevis are approached and released from the undersurface using a shaver through the superior-lateral portal. The lateral epicondyle may be decorticated with a burr, although caution must be taken not to cause iatrogenic elbow instability via disruption of the lateral collateral ligament complex.<sup>6,33</sup>

Open release is the most common approach, and the classic method is that described by Nirschl and Pettrone<sup>15</sup> in 1979, although modern “mini-open” techniques have further modified the original description.<sup>35</sup> A 3-cm curvilinear incision is placed over the lateral epicondyle, and the interface between the extensor carpi radialis longus and the common extensor tendon is visualized and then divided. The extensor digitorum communis is detached subperiosteally, and the deeper extensor carpi radialis brevis is exposed and often appears grey, edematous, and friable (**Figure 3**).



**Figure 3** The mini-open procedure for lateral epicondylitis is shown. The extensor carpi radialis brevis tendon lies deep to the interval between the extensor carpi radialis longus and the extensor digitorum communis. (A) Note the grey, edematous, and friable-appearing tissue of the extensor carpi radialis brevis tendon within the forceps. (B) The degenerated extensor carpi radialis brevis tendon origin is resected (area depicted by the dotted triangle). Photographs are courtesy of Brian Reiter, MD. ECRB = extensor carpi radialis brevis; ECRL = extensor carpi radialis longus; EDC = extensor digitorum communis.

The degenerated undersurface is debrided, and the lateral epicondyle is decorticated to expose a bleeding surface. A side-to-side repair of the extensor mechanism is performed followed by closure of the skin. Patients usually resume office work by 3 to 5 days and heavier lifting by 3 weeks after surgery.

## CONCLUSIONS

The open approach leads to greater visualization of the operative field and pathologic tissue; however, it is associated with a higher incidence of complications and a longer time to return to work.<sup>34</sup> The arthroscopic approach leads to a shorter recovery, but it is more technically demanding.<sup>33</sup> Currently, the literature does not support the superiority of any one technique; surgical treatment for tennis elbow predominately results in good to excellent outcomes, and success rates approaching 97% have been reported.<sup>6,24,33-36</sup>

## References

- Morris HP. Lawn-tennis elbow. *Br Med J*. 1883;2:557.
- Boyer MI, Hastings H II. Lateral tennis elbow: "Is there any science out there?" *J Shoulder Elbow Surg*. 1999;8:481-491.
- Priest JD, Braden V, Gerberich JG. The elbow and tennis. Part 1. *Phys Sports Med*. 1980;8:80.
- De Smedt T, de Jong A, Leemput WV, et al. Lateral epicondylitis in tennis: update on aetiology, biomechanics, and treatment. *Br J Sports Med*. 2007;41:816-819.
- Giangarra CE, Conroy B, Jobe FW, et al. Electromyographic and cinematographic analysis of elbow function in tennis players using single- and double-handed backhand strokes. *Am J Sports Med*. 1993; 21:394-399.
- Calfee RP, Patel A, DaSilva MF, et al. Management of lateral epicondylitis: current concepts. *J Am Acad Orthop Surg*. 2008;16:19-1629.
- Shiri R, Viikari-Juntura E. Lateral and medial epicondylitis: role of occupational factors. *Best Pract Res Clin Rheumatol*. 2011;25:43-57.
- Shiri R, Viikari-Juntura E, Varonen H, et al. Prevalence and determinants of lateral and medial epicondylitis: a population study. *Am J Epidemiol*. 2006;164:1065-1074.
- Morris M, Jobe FW, Perry J, et al. Electromyographic analysis of elbow function in tennis players. *Am J Sports Med*. 1989;17:241-247.
- Orchard J, Kountouris A. The management of tennis elbow. *BMJ*. 2011;342:d2687.
- Bunata RE, Brown DS, Capelo R. Anatomic factors related to the cause of tennis elbow. *J Bone Joint Surg*. 2007;89A:1955-1963.
- Tanaka Y, Aoki M, Izumi T, et al. Effect of elbow and forearm position on contact pressure between the extensor origin and the lateral side of the capitellum. *J Hand Surg*. 2011;36A:81-88.
- Thurston AJ. Conservative and surgical treatment of tennis elbow: a study of outcome. *Aust N Z J Surg*. 1998;68:568-572.
- Hume PA, Reid D, Edwards T. Epicondylar injury in sport: epidemiology, type, mechanisms, assessment, management and prevention. *Sports Med*. 2006;36:151-170.
- Nirschl RP, Pettrone FA. Tennis elbow. The surgical treatment of lateral epicondylitis. *J Bone Joint Surg Am*. 1979;61:832-839.
- Unverferth LJ, Olix ML. The effect of local steroid injections on tendon. *J Sports Med*. 1973;1:31-37.
- Gardner RC. Tennis elbow: diagnosis, pathology and treatment: nine severe cases treated by a new reconstructive operation. *Clin Orthop*. 1970;72:248-253.
- Coonrad RW, Hooper WR. Tennis elbow: its course, natural history, conservative and surgical management. *J Bone Joint Surg Am*. 1973; 55:1177-1182.
- Stasinopoulos D, Johnson MI. Cyriax physiotherapy for tennis elbow/lateral epicondylitis. *Br J Sports Med*. 2004;38:675-677.
- Tyler TF, Thomas GC, Nicholas SJ, et al. Addition of isolated wrist extensor eccentric exercise to standard treatment for chronic lateral epicondylitis: a prospective randomized trial. *J Shoulder Elbow Surg*. 2010;19:917-922.
- Snyder-Mackler L, Epler M. Effect of standard and Aircast tennis elbow bands on integrated electromyography of forearm extensor musculature proximal to the bands. *Am J Sports Med*. 1989;17:278-281.
- Eyendaal D, Rahussen FTG, Diercks RL. Biomechanics of the elbow joint in tennis players and relation to pathology. *Br J Sports Med*. 2007;41:820-823.

23. Hatch GF, Pink MM, Mohr KJ, et al. The effect of tennis racket grip size on forearm muscle firing patterns. *Am J Sports Med.* 2006;34:1977-1983.
24. Jobe FW, Ciccotti MG. Lateral and medial epicondylitis of the elbow. *J Am Acad Orthop Surg.* 1994;2:1-8.
25. Labelle H, Guilbert R, Joncas J, et al. Lack of scientific evidence for the treatment of lateral epicondylitis of the elbow. An attempted meta-analysis. *J Bone Joint Surg Br.* 1992;74:646-651.
26. Labelle H, Guilbert R. Efficacy of diclofenac in lateral epicondylitis of the elbow as treated with immobilization. *Arch Fam Med.* 1997;6:257-262.
27. Hayton MJ, Santini AJ, Hughes PJ, Frostick SP, Trail IA, Stanley JK. Botulinum toxin injection in the treatment of tennis elbow. A double-blind, randomized, controlled, pilot study. *J Bone Joint Surg Am.* 2005;87:503-507.
28. Johnson GW, Cadwallader K, Scheffel SB, et al. Treatment of lateral epicondylitis. *Am Fam Physician.* 2007;76:843-848.
29. Bisset L, Beller E, Jull G, et al. Mobilisation with movement and exercise, corticosteroid injection, or wait and see for tennis elbow: a randomised trial. *BMJ.* 2006;333:939.
30. Gosens T, Peerbooms JC, van Laar W, et al. Ongoing positive effect of platelet-rich plasma versus corticosteroid injection in lateral epicondylitis: a double-blind randomized controlled trial with 2-year follow-up. *Am J Sports Med.* 2011;39:1200-1208.
31. Thanasis C, Papadimitriou G, Charalambidis C, et al. Platelet-rich plasma versus autologous whole blood for the treatment of chronic lateral elbow epicondylitis: a randomized controlled clinical trial. *Am J Sports Med.* 2011;39:1230-1234.
32. Wolf JM, Ozer K, Scott F, et al. Comparison of autologous blood, corticosteroid, and saline injection in the treatment of lateral epicondylitis: a prospective, randomized, controlled multicenter study. *J Hand Surg Am.* 2011;36:1269-1272.
33. Othman AMA. Arthroscopic versus percutaneous release of common extensor origin for treatment of chronic tennis elbow. *Arch Orthop Trauma Surg.* 2011;131:383-388.
34. Dunkow PD, Jatti M, Muddu BN. A comparison of open and percutaneous techniques in the surgical treatment of tennis elbow. *J Bone Joint Surg (Br).* 2004;86-B:701-704.
35. Dunn JH, KIM JJ, Davis L, Nirschl RP. Ten to 14 year follow-up of the Nirschl surgical technique for lateral epicondylitis. *Am J Sports Med.* 2008;36:261-266.
36. Karkhanis S, Frost A, Maffulli N. Operative management of tennis elbow: a quantitative review. *Br Med Bull.* 2008;88:171-188.