

Advances and challenges in neurostimulation for headaches

Delphine Magis, Jean Schoenen

Lancet Neurol 2012; 11: 708–19

Headache Research Unit,
Department of Neurology
(D Magis MD, J Schoenen MD),
and GIGA Neurosciences
(J Schoenen), University of
Liège, Belgium

Correspondence to:
Prof Jean Schoenen, Headache
Research Unit, Boulevard du
12ème de Ligne 1,
4000 Liège, Belgium
jschoenen@ulg.ac.be

Many people who suffer from primary headache (ie, headache without an identifiable cause) are resistant or intolerant to available drugs. During the past decade, central and peripheral neurostimulation procedures have been investigated in such individuals—up to now, about 1200 worldwide. Techniques used range from invasive methods such as deep brain stimulation of the posterior hypothalamus, to minimally invasive percutaneous electrode implantation used in occipital nerve stimulation, or non-invasive methods such as transcranial magnetic stimulation. Although some of these procedures have been studied extensively, sham-controlled trials are sparse and the precise mode of action of such stimulation remains largely unknown. Nonetheless, occipital nerve stimulation and deep brain stimulation of the posterior hypothalamus seem to be effective in people with chronic cluster headache, and occipital nerve stimulation is promising in chronic migraine. Trial data for other techniques are scarce, but external and minimally invasive approaches should be privileged in future studies.

Introduction

Primary headaches—ie, headaches without an identifiable underlying cause—affect about 46% of the general population¹ and are a socioeconomic burden. Their chronic forms, characterised by daily or almost daily headache, are the most disabling and have a prevalence of 3%. The main diagnostic entities, as defined in the second edition of the International Headache Classification (table 1), are migraine,² tension-type headache, and trigeminal autonomic cephalalgias, which comprise cluster headache, paroxysmal hemicrania, short-lasting unilateral neuralgiform headache with conjunctival injection and tearing (also known as SUNCT), and hemicrania continua.

Effective treatments are available for most primary headaches but they are not sufficient for patients who have frequent attacks, and when such treatments are used frequently they can induce medication-overuse headache. Hence, preventive treatments with disease-modifying properties are necessary in the most affected individuals. Unfortunately, the rate of response to the best preventive drugs does not exceed 50% and is even lower in chronic forms of the disorder.³ The most active antimigraine drugs have high rates of side-effects. Thus, many people who suffer with chronic headache are either resistant or intolerant to available pharmacological treatments and meet the definition of intractability.⁴

Of alternative treatments, neurostimulation is not a novel approach. In the 1st century, Emperor Claudius' doctor, Scribonius Largus, recommended application of a live electric fish (*Torpedo marmorata*) on the site of head pain. Interest in use of neurostimulation methods for headache has grown in the past decade, and this approach has superseded most lesional procedures that were used in patients with intractable headache.

Many methods for treatment of primary headache have been studied, ranging from invasive deep brain stimulation to minimally invasive percutaneous electrode implantations or non-invasive transcutaneous stimulation (figure). The quality of evidence for these various approaches is highly variable. Here, we review central and peripheral neurostimulation techniques that have been

assessed for headache. Furthermore, we discuss available evidence for their rationale, effectiveness, safety, and mode of action. Finally, we attempt to identify some prospects for neurostimulation in headache disorders.

Central neurostimulation methods

Deep brain stimulation

By contrast with spinal-cord stimulation and, to a lesser extent, motor-cortex stimulation, deep brain stimulation is used infrequently nowadays for chronic pain disorders.⁵ The rationale for deep brain stimulation of the ventroposterior hypothalamus in patients with refractory cluster headache stems from findings of imaging studies showing that this area is hyperactive during attacks⁶ and that grey-matter density is increased in these patients.⁷ These data led to the hypothalamic implantation of stimulating electrodes by Leone and colleagues,⁸ with good results in two patients. Subsequently, worldwide, more than 60 people were implanted with such electrodes, and the method was extended to individuals with other types of trigeminal autonomic cephalalgia (table 2).

Table 3 lists the results obtained with posterior hypothalamic deep brain stimulation in 64 patients with drug-resistant chronic cluster headache.^{9–22} The overall success rate (ie, patients becoming pain-free or with $\geq 50\%$ improvement) is 64% and mean follow-up is 1.6 years. In the largest series to date ($n=16$),¹¹ after mean follow-up of 23 (range 1–52) months, ten patients were pain-free and three others had only sporadic attacks. Mean time to obtain a clinically significant headache reduction was 42 days (range 1–86). Most people who switched their stimulator off or had a flat battery had recurrence of attacks after only a short delay, which was also described for other neurostimulation techniques such as occipital nerve stimulation^{23,24} and suggests that the treatment is only symptomatic. Fontaine and colleagues²⁰ undertook a randomised, double-blind, placebo-controlled trial of posterior hypothalamic deep brain stimulation in drug-resistant chronic cluster headache, in which 11 patients underwent either effective or sham stimulation for 2 months. No difference was noted between the two

	Migraine	Cluster headache	Paroxysmal hemicrania	SUNCT	Hemicrania continua
ICHD-II classification code	1-1 without aura; 1-2 with aura; 1-5-1 chronic migraine	3-1	3-2	3-3	4-7
Frequency in general population	15% (2% chronic)	0-1%	Rare	Very rare	Rare
Sex ratio	Women>men	Men>women	Women>men	Men>women	Women>men
Headache type	Moderate to severe; unilateral or bilateral; prostration	Severe; unilateral; agitation	Moderate to severe; unilateral	Neuralgiform discharge; unilateral	Moderate background pain; severe exacerbations; unilateral
Autonomic signs	Sometimes	Yes	Yes	Yes	Yes (exacerbations)
Headache duration	Hours	15-180 min	2-30 min	5-240 s	Continuous
Headache frequency	Highly variable	1-2 to 8 attacks a day	5-40 attacks a day	3-200 attacks a day	Not applicable
Periodicity	Episodic or chronic (ie, >15 days a month for at least 3 months); no rhythm except menses	Episodic or chronic; circadian and circannual	Episodic or chronic	Episodic or chronic	Not applicable
First-choice prophylaxis	Valproate; topiramate; β blockers; amitriptyline	Verapamil; steroids; lithium	Indometacin	Anticonvulsants	Indometacin (diagnostic criteria)

ICHD-II=International Headache Classification, 2nd edn. SUNCT=short-lasting unilateral neuralgiform headache with conjunctival injection and tearing.

Table 1: Principal characteristics of main primary headaches

study arms, probably because of the short duration of the treatment phase. Indeed, in a subsequent 10-month open-label phase, during which all patients received effective stimulation, three became pain free and three others had a 50% or greater reduction in attack frequency.

Three patients with SUNCT were treated with posterior hypothalamic deep brain stimulation.²⁵⁻²⁷ One person became pain free but then needed additional prophylaxis with lamotrigine.²⁵ A second individual had a substantial reduction in attack frequency, from 120 per day to 25 per day after 1 year.²⁶ The third patient²⁷ had a reduction in attack frequency from 30 per day to a few sporadic attacks after 15 months of posterior hypothalamic deep brain stimulation. Walcott and co-workers²⁸ also reported relief from attack in an individual with chronic paroxysmal hemicrania.

The effectiveness of posterior hypothalamic deep brain stimulation to treat attacks of cluster headache has been assessed by Leone and colleagues in a series of 16 patients.²⁹ Treatment consisted of switching on the stimulator if it was off or increasing stimulation intensity when the attack happened. A total of 136 attacks were treated, of which 108 were assessable (intolerable side-effects arose during the remaining 28 attacks). A clinically significant reduction in pain intensity (ie, $\geq 50\%$) was noted in 25 attacks (23%), suggesting posterior hypothalamic deep brain stimulation is not useful for acute treatment of cluster headache.

Posterior hypothalamic deep brain stimulation is not a riskless procedure (table 3). One patient died from an intracerebral haemorrhage along the electrode track a few hours after implantation⁹ and another had a subclinical haemorrhage.¹¹ Overall, although the number of reported cases remains small, the risk of bleeding is around 3%, which is within the upper range reported for deep brain stimulation in movement disorders. Various

procedures have been proposed to minimise bleeding risk²² but are not yet fully validated. Other reported adverse events are panic attack with dysautonomia,⁹ oculomotor disturbances,^{9,20,22} intraoperative transient ischaemic attack,¹³ subcutaneous infection,²⁰ transient loss of consciousness with hemiparesis and micturition syncope,²⁰ erectile dysfunction,²⁶ headache and tremor,²¹ euphoria,²² and paroxysmal sneezing.³⁰ Posterior hypothalamic deep brain stimulation has no deleterious effect on sleep quality and, instead, improves it by suppression of nocturnal attacks.³¹ Switching on the stimulator does not modify heart rate, blood pressure, or respiratory rate under resting conditions.³²

The precise mode of action of posterior hypothalamic deep brain stimulation in trigeminal autonomic cephalalgias remains obscure. By contrast with deep brain stimulation for movement disorders, no clinical or physiological marker can be used to assess correct positioning of the hypothalamic electrode. Microelectrode recordings have failed to identify a specific neuronal firing pattern,^{11,18} even when stimulations were applied in the trigeminal nerve territory.¹⁸ Spontaneous slow regular discharges of about 13.2 Hz have been recorded in posterior hypothalamic neurons, contrasting with the faster discharge rate (28 Hz [SD 8.2]) of more dorsally located medial thalamic neurons.³³ Local field-potential recordings indicate raised neuronal activity in the targeted posterior hypothalamus during attacks.³⁴ In an MRI study of the exact location of stimulating electrodes in ten patients with drug-resistant chronic cluster headache, Fontaine and co-workers³⁵ noted that the target was posterior to the hypothalamus—ie, posterior to the mammillary bodies—in an area bridging the hypothalamus and the mesencephalic grey substance and containing several fibre tracts, such as the dorsal longitudinal fascicle, the mammillo-tegmental fascicle,

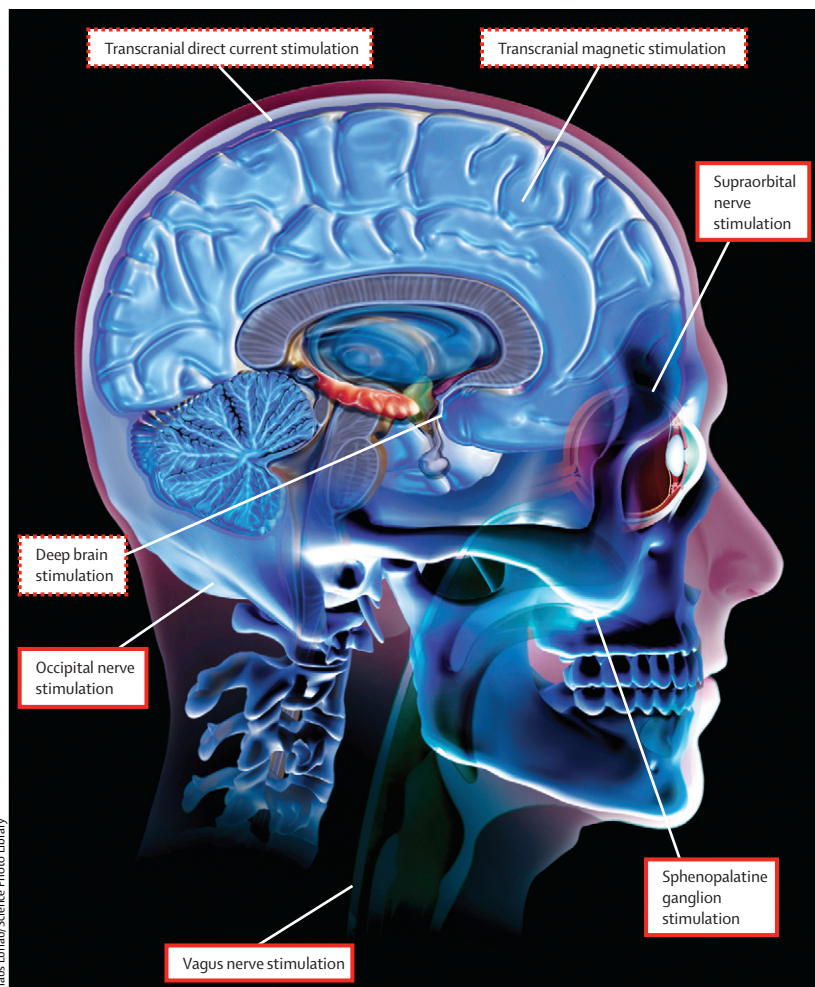


Figure: Stimulation sites for headache treatment

Dashed lines represent central neuromodulation techniques and continuous lines are peripheral techniques.

and the fascicle retroflexus of Meynert. No difference was recorded in anatomical location of stimulating electrodes between responders and non-responders.

In an $H_2^{15}O$ -PET study of ten Italian patients undergoing posterior hypothalamic deep brain stimulation, activation or deactivation in several areas of the pain neuromatrix was noted in addition to activation of the stimulated hypothalamic area.³⁶ The effect of posterior hypothalamic deep brain stimulation on trigeminal perception and pain thresholds was subtle. Algometric and electrophysiological measurements show that pain perception was moderately decreased in peripheral limbs, but recorded no lasting effect on electrical pain thresholds or nociceptive reflexes in the trigeminal territory.⁹ In another study, 11 patients with drug-resistant chronic cluster headache treated with posterior hypothalamic deep brain stimulation had a higher degree of cold detection and an augmented cold pain threshold ipsilaterally in the territory of the ophthalmic nerve.³⁷ Together, these physiological findings suggest that the effectiveness of

posterior hypothalamic deep brain stimulation in chronic cluster headache is not attributable to a simple analgesic effect, the therapeutic effect is probably not related to direct hypothalamic stimulation, and failure of posterior hypothalamic deep brain stimulation treatment could be due to factors unrelated to electrode misplacement. Despite many clinical observations that interruption of stimulation is followed by recurrence of attacks, a placebo effect or amelioration due to the natural history of the disorder has not been excluded definitively.^{9,11}

Transcranial magnetic stimulation

Transcranial magnetic stimulation has been used in clinical neurophysiology for more than 20 years. It is a simple and relatively safe way to modulate excitability of the underlying cerebral cortex (depolarisation or hyperpolarisation), using a rapidly changing magnetic field applied at the scalp surface, and it can be delivered as either one pulse or trains of repeated stimulations. Repetitive transcranial magnetic stimulation is effective for pain relief in fibromyalgia.³⁸ However, transcranial magnetic stimulation was first used as a pathophysiological method to study cortical excitability and preactivation levels in migraine.^{39–41} Repetitive stimulation can induce long-lasting changes in the underlying cortex (eg, responsiveness of visual cortex in man),⁴⁰ either by inhibition at low stimulation frequencies (eg, 1 Hz)⁴² or by activation at high frequencies (≥ 10 Hz).⁴³ In animals, single-pulse transcranial magnetic stimulation can disrupt cortical spreading depression.⁴⁴ Findings in patients and animals have paved the way for therapeutic trials in migraine.

In 42 patients with migraine, Clarke and colleagues⁴⁵ compared the effect of two single pulses of high (50% of maximum 2.3 T output) and low (30% of output) intensity transcranial magnetic stimulation over the painful area (migraine without aura) or the occipital cortex (migraine with aura). Both low and high intensity stimulation relieved headache, and 32% of patients had no headache recurrence 24 h after stimulation. An immediate effect on headache was reported in all patients who had aura. Subsequently, a randomised sham-controlled study in 164 patients was undertaken with a portable transcranial magnetic stimulation device delivering two single pulses at 30 s intervals over the occiput within the first hour of aura onset.⁴⁶ Pain-free response rates at 2 h were 39% for transcranial magnetic stimulation and 22% for the sham control. Although this result was significant, the therapeutic gain of 17% is not impressive. Sustained pain-free rates at 24 h and 48 h were in favour of transcranial magnetic stimulation, yet the global assessment of relief was better in the sham arm than in the transcranial magnetic stimulation arm. Furthermore, headache response at 2 h, use of acute medication, or consistency of response did not differ between groups.⁴⁶ Therefore, the usefulness of

	Treatment type	Studies (n)	Patients (n)	Main results
Central modulation				
Posterior hypothalamic deep brain stimulation				
Chronic cluster headache	Prophylaxis	14	64	64% frequency improvement (42% pain free; table 3)
Chronic cluster headache	Acute treatment	1	16	23% headache relief
SUNCT	Prophylaxis	3	3	Positive results, none pain-free
Paroxysmal hemicrania	Prophylaxis	1	1	Initial relief
Single-pulse transcranial magnetic stimulation				
Migraine with aura (and without)	Acute treatment	2	206	Mixed results
High frequency repetitive transcranial magnetic stimulation				
Chronic migraine	Prophylaxis	2	24	Mixed results
Low frequency repetitive transcranial magnetic stimulation				
Migraine with and without aura	Prophylaxis	1	27	Frequency improvement, no difference with placebo
Transcranial direct current stimulation				
Chronic migraine	Acute treatment	1	62	Pain decrease, no difference with placebo
Cathodal transcranial direct current stimulation				
Migraine with and without aura	Prophylaxis	1	26	No difference with placebo except for headache intensity
Anodal transcranial direct current stimulation				
Chronic migraine	Prophylaxis	1	13	Delayed positive results on pain and length of migraine episodes
High spinal cord stimulation				
Chronic cluster headache	Prophylaxis	1	7	77% frequency improvement on average
Peripheral modulation				
Occipital nerve stimulation				
Chronic cluster headache	Prophylaxis	9	91	67% improvement on average (table 4)
SUNA	Prophylaxis	2	3	Almost complete cessation of the attacks
SUNCT	Prophylaxis	2	9	At least 50% improvement
Hemicrania continua	Prophylaxis	2	8	Six of eight improved
Chronic migraine	Prophylaxis	10	500	56% improvement on average (table 5)
Sphenopalatine ganglion stimulation				
Chronic cluster headache	Acute treatment	1	6	Complete resolution in 11 of 18 treated attacks
Chronic cluster headache	Acute treatment and prophylaxis	1	20	17 of 20 improved in frequency or headache intensity
Chronic migraine	Acute treatment	1	11	Five of 11 attacks improved by stimulation; two patients were pain free
Vagus nerve stimulation				
Episodic migraine	Prophylaxis	2	14	11 of 14 improved in frequency
Chronic migraine	Prophylaxis	3	9	Five of nine improved in frequency
Chronic cluster headache	Prophylaxis	1	2	Two of two improved in frequency
Auriculotemporal nerve stimulation				
Chronic migraine	Prophylaxis	1	1	Pain relief
Supraorbital nerve stimulation				
Episodic migraine	Acute treatment	1	10	Pain freedom in 13% only
Trigeminal autonomic cephalgia	Acute treatment	1	5	Pain intensity decreased from 8.9 to 1.6 on a visual analogue scale
Episodic and chronic migraine	Prophylaxis	3	65	56% improvement in frequency on average

SUNCT=short-lasting unilateral neuralgiform headache with conjunctival injection and tearing. SUNA=short-lasting unilateral neuralgiform headache with autonomic symptoms.

Table 2: Central and peripheral neurostimulation techniques in headaches

transcranial magnetic stimulation for acute treatment of migraine remains to be established.

Repetitive transcranial magnetic stimulation has been investigated for prevention of migraine in a few small

studies (table 2).⁴⁷⁻⁴⁹ Working under the assumption that the left dorsolateral prefrontal cortex exerts a pain-reducing top-down control and is hypoactive in chronic migraine, similar to in other chronic pain disorders,

	Patients (n)	Follow-up (years)	Pain-free patients (n)	At least 50% improvement in headache frequency and/or intensity (n)	Side-effects
Schoenen (2005) ⁹	6	4	2	1	Fatal haemorrhage; panic attack; oculomotor disturbances
D'Andrea (2006) ¹⁰	3	2.5	2	0	..
Leone (2006) ¹¹	16	2	10	0	Subclinical haemorrhage
Benabid (2006) ^{*12}	1	1	1	0	..
Starr (2007) ¹³	4	1	0	2	Transient ischaemic attack
Owen (2007) ¹⁴	1	0.7	1	0	..
Bartsch (2009) ¹⁹	2	2	0	0	..
Mateos (2007) ^{*16}	2	1	1	1	..
Black (2007) ^{*15}	2	2.6	0	2	..
Bartsch (2008) ¹⁸	6	1.4	2	1	..
Piacentino (2008) ^{*17}	4	>0.4	3	1	..
Fontaine (2010) ²⁰	11	1	3	3	Subcutaneous infection; transient loss of consciousness with hemiparesis; micturition syncope
Hidding (2011) ²¹	1	NR	0	0	Headache; high frequency tremor
Seijo (2011) ²²	5	2.8	2	3	Euphoria, well being; dizziness and oculomotor disturbances; concentration difficulties; headache, cervical dystonia; increased appetite
Total	64	..	27 (42%)	14 (22%)	..

NR=not reported. *Data published in abstract form only.

Table 3: Main studies of posterior hypothalamic deep brain stimulation in drug-resistant chronic cluster headache

Brighina and colleagues applied high frequency repetitive transcranial magnetic stimulation to this area (20 Hz, 12 sessions, 400 pulses per session, 90% of motor output) in six people with chronic migraine; a further five received sham stimulation. Attack frequency, headache index, and number of abortive pills used was reduced significantly by repetitive transcranial magnetic stimulation, and this effect lasted for up to 2 months.⁴⁷ However, these favourable results were not reproduced in a study of 13 patients with chronic migraine,⁴⁸ in whom 10 Hz repetitive transcranial magnetic stimulation was applied over the dorsolateral prefrontal cortex and was less effective than sham stimulation. Postulating that the migrainous brain is hyperexcitable between attacks and that low frequency repetitive transcranial magnetic stimulation might return this hyperexcitability to normal, Teepker and colleagues⁴⁹ applied 1 Hz stimulation (two trains of 500 pulses at motor threshold on five consecutive days) over the vertex for prevention in 27 patients with episodic migraine with or without aura. Number of migraine attacks and days did not differ significantly between repetitive transcranial magnetic stimulation and sham stimulation.

The negative outcome of Teepker's study⁴⁹ could be attributable to an incorrect rationale. Also, the effects of repetitive transcranial magnetic stimulation might not be linear but could depend on the baseline activation level of the underlying cortex,⁵⁰ which is important for migraine because the cortical preactivation level in this disorder seems to be reduced.⁵¹ Repetitive transcranial magnetic stimulation can promote long-lasting plastic changes, leading to functional reorganisation of the underlying cortex, and even single-pulse transcranial magnetic stimulation can engage several brain networks that are connected functionally to the visual system,⁵² which might be relevant for its effects in migraine.

Transcranial direct current stimulation

Transcranial direct current stimulation is another non-invasive and safe brain stimulation technique. It uses weak currents to modify the resting membrane potential, leading to focal modulation of cortical excitability. Cathodal transcranial direct current stimulation inhibits neuronal firing whereas anodal stimulation increases it. Various chronic pain syndromes can be treated successfully with anodal transcranial direct current stimulation over the primary motor cortex.⁵³

The effect of transcranial direct current stimulation during migraine attacks was studied in 62 patients.⁵⁴ Both transcranial direct current stimulation (polarity not mentioned) and sham stimulation led to a 54.2% reduction in headache intensity, suggesting a non-specific effect.

Antal and colleagues⁵⁵ compared the effects of cathodal transcranial direct current stimulation and sham stimulation applied three times a week for 6 weeks over the primary visual cortex in 26 patients with episodic migraine, under the assumption that the cortex is hyperexcitable between attacks. Although migraine days, duration, and intensity fell significantly from baseline after transcranial direct current stimulation, this change did not differ from sham stimulation, except for intensity. Side-effects were minor and transient. Based on the opposite rationale, Dasilva and co-workers⁵⁶ undertook a sham-controlled trial in 13 people with chronic migraine and applied anodal transcranial direct current stimulation over the primary motor cortex. A delayed effect on pain intensity and duration (ie, 120 days after stimulation) was noted, which was attributed to slow modulation of pain neuromatrix structures.

Although the amplitude of pain-related cortical evoked potentials rose slightly with anodal transcranial direct current stimulation of the motor cortex and fell with cathodal stimulation, no effect was seen on the nociception-specific blink reflex, suggesting that the brainstem is not affected by transcranial direct current stimulation.⁵⁷ In healthy volunteers, transcranial direct current stimulation modulated resting EEG and event-related potentials⁵⁸ and functional connectivity of

corticostriatal and thalamocortical circuits.⁵⁹ This effect might be relevant for migraine associated with a thalamocortical dysrhythmia.⁶⁰ Findings of animal studies are also important for migraine with aura, showing that cortical spreading depression can be affected by transcranial direct current stimulation.⁶¹

Peripheral neurostimulation methods

Peripheral neurostimulation is a minimally invasive and non-destructive approach to pain control that has been used for several decades. Its analgesic effects have been attributed not only to activation of afferent A β fibres and gate control in the spinal cord⁶² but also to descending supraspinal control from the rostroventromedial medulla or the periaqueductal grey matter.⁶³

Occipital nerve stimulation

In 1999, Weiner and Reed⁶⁴ used occipital nerve stimulation to successfully treat drug-resistant occipital neuralgia. This work opened the way for observational studies of this non-harmful method of neurostimulation in various chronic primary headache disorders.

Table 4 presents data for occipital nerve stimulation in drug-resistant chronic cluster headache.^{23,24,65-73} In three trials, the success rate of occipital nerve stimulation was similar to that for posterior hypothalamic deep brain stimulation.^{24,66,72} Burns and colleagues^{65,66} reported data from 14 patients receiving an implant, with follow-up of 3–35 months. Three people had striking improvement ($\geq 90\%$), three reported moderate amelioration (40–60%), and four showed mild improvement (20–30%).⁶⁶ We followed up prospectively 15 patients with drug-resistant chronic cluster headache for up to 5 years after implantation of occipital nerve stimulation (mean 36.8 months).^{23,24} One patient had an immediate post-operative infection. Of the 14 remaining individuals, 11 (79%) had a 90% reduction or greater in attack frequency and nine (60%) remained pain-free for long periods (months to years). Preventive drugs were reduced in four (29%), but only one responder could stop all drugs. The intensity of residual attacks was not modified by occipital nerve stimulation.²⁴ In another prospective study of occipital nerve stimulation in 13 patients with drug-resistant chronic cluster headache,⁷² attack frequency fell on average by 68% and intensity decreased by 49%. Eight of 13 patients were able to reduce or stop preventive drugs. In other smaller studies, beneficial outcomes with occipital nerve stimulation have been recorded.^{67-71,73} In the trials presented in table 4, time to achieve an improvement was variable—eg, from 3 days to 18 months (one immediate),⁶⁶ mean 4.83 (SD 2.5) months,²⁴ and a few days to 5 months.⁷²

In patients with chronic migraine (table 5),⁷⁴⁻⁸³ Popeney and colleagues⁷⁴ noted an 88.7% improvement on the migraine disability assessment score (MIDAS) and no or little residual disability in 15 of 25 patients. Matharu and co-workers⁷⁵ described briefly the clinical evolution

of patients treated with occipital nerve stimulation (six of eight had amelioration) in a PET study. Schwedt and colleagues⁷⁶ studied a mixed population of 15 individuals refractory to drugs, and four of eight with chronic migraine had a striking improvement. Preliminary findings of a controlled study of occipital nerve stimulation in chronic migraine (ONSTIM study)⁷⁹ indicated at least a 50% reduction in headache frequency or a fall of 3 points on the intensity scale in 11 (39%) patients treated with active occipital nerve stimulation during 3 months, whereas no improvement was seen in non-stimulated or ineffectively stimulated groups. Silberstein and colleagues⁸⁰ undertook a large study of 157 patients with chronic migraine, who were randomly allocated either active occipital nerve stimulation or control (sham stimulation) during a 3-month period, followed by an open-label phase up to 52 weeks. At 12 weeks, MIDAS headache days fell by 22.5 in the active group and 3.4 in the control group, and scores on a visual analogue scale decreased by 14.1 in the active arm and by 7 in the control arm. Individuals treated with active occipital nerve stimulation also had decreased MIDAS scores, better quality of life, and were more satisfied.⁸⁰ In the sham-controlled PRISM study,⁷⁷ occipital nerve stimulation did not produce any substantial reduction in headache days in 125 patients with migraine refractory to drugs who completed a 12-week assessment period. Heterogeneity of the cohort could account for these results (patients had migraine with or without aura, chronic migraine, and drug overuse headache), because patients who had overused medication, for example, had a less favourable outcome. This idea was also suggested in a retrospective study of various types of headaches treated with occipital nerve stimulation.⁸⁴ The estimated success rate of occipital nerve stimulation in chronic migraine is slightly lower than for drug-resistant chronic cluster headache. In a series of seven patients with chronic migraine,⁸⁵ a combination of suboccipital and supraorbital neurostimulation produced an improvement in headache frequency of 90% or more in all patients. However, no clinically significant response was noted for either stimulation type alone.

Schwedt and colleagues⁷⁶ reported two patients with hemicrania continua who were treated successfully with occipital nerve stimulation. Burns and co-workers⁸⁶ used a bion microstimulator in six people with hemicrania continua (follow-up 6–21 months). Four patients had pain reduction of 80–90%.

With respect to other headache types, nine patients with intractable SUNCT and three with short-lasting unilateral neuralgiform headache attacks with autonomic symptoms (SUNA) showed a benefit of at least 50% with occipital nerve stimulation, and four patients were nearly pain free after around 14 months of follow-up.^{87,88} Marin and Goadsby⁸⁹ reported four cases of primary stabbing headache treated with occipital nerve stimulation: in

	Patients (n)	Follow-up (months)	At least 50% improvement in headache frequency and/or intensity (n)	Side-effects
Magis (2007 and 2011) ^{32,34}	15	36.8	12	Empty battery
Burns (2007 and 2009) ^{65,66}	14	17.5	5	Empty battery; electrode migration; infection
Proietti Cecchini (2009) ⁶⁷	13	21	8	Empty battery
Lara Lara (2009) ⁶⁸	6	6–15	4	..
De Quintana-Schmidt (2010) ⁶⁹	4	6	4	..
Salom (2010) ⁷⁰	14	NR	7	Infection
Müller (2010) ⁷¹	10	12	9	Infection
Fontaine (2011) ⁷²	13	14.6	10	Empty battery
Strand (2011) ⁷³	3	12	2	..
Total	91	..	61 (67%)	..

NR=not reported. *Data published in abstract form only.

Table 4: Main studies of occipital nerve stimulation in drug-resistant chronic cluster headache

	Patients (n)	Follow-up (months)	Main findings	Side-effects
Popeney (2003) ⁷⁴	25	18.3	64% of patients improved by at least 50%	Lead migration; infection
Matharu (2004) ⁷⁵	8	18	100% of patients improved by at least 50%	Abdominal haematoma; lead migration
Schwedt (2007) ⁷⁶	8	19	50% of patients improved by at least 50%	Lead migration
Lipton (2009) ⁷⁷	125	3	No difference vs sham	Infection; site pain; sensory symptoms
Marchioretto (2010) ⁷⁸	34	12	Overall 56% frequency reduction	Mild
Saper (2011) ⁷⁹	66	3	39% of patients improved by at least 50%	Lead migration; infection
Silberstein (2011) ⁸⁰	157	3	Reduction in headache days by 36%	Infection
Reed (2011) ⁸¹	44	13	Overall 57% frequency reduction	..
Narouze (2011) ⁸²	12	13	Overall 81% frequency reduction	Slight lead migration
Linder (2011) ⁸³	13	NR	Overall 80% frequency reduction (60% pain free)	..
Total	500	..	About a 56% improvement	..

NR=not reported. *Data published in abstract form only. †Used a combination of suboccipital and supraorbital neurostimulation.

Table 5: Main studies of occipital nerve stimulation in chronic migraine

three, the jabs and jolts stopped and in one they were diminished greatly.

A technique similar to occipital nerve stimulation but riskier is epidural high cervical spinal cord stimulation, which was assessed in seven patients with drug-resistant chronic cluster headache.⁹⁰ An immediate improvement was seen in headache frequency (a fall from 6 to 1.4 attacks a day) and intensity (a reduction from 7.4 to 4.5 on a 10-point scale).

Occipital nerve stimulation is relatively safe compared with deep brain stimulation. The most frequent adverse events are lead migration and local immediate or delayed infections (tables 4 and 5). The frequency of lead migration needing revision differs between research

groups (ranges from 0%²⁴ to 100%)⁷⁶ and seems to depend on the operator and surgery. Another technical difficulty is battery depletion, leading to surgery for replacement in 64% of patients.²⁴ Battery depletion arises because of the high current intensities needed to obtain effective occipital nerve stimulation and can be overcome by use of rechargeable batteries. From the patient's perspective, unpleasant traction on the connecting cables and stimulation-induced paraesthesias are frequently reported side-effects.²⁴ Development of hemispheric continua was described in two patients receiving effective occipital nerve stimulation for SUNCT and SUNA, on the pain side.⁸⁷ Because of a side-shift in their first implanted patient with drug-resistant chronic cluster headache, Burns and colleagues⁶⁵ decided to implant subsequent patients bilaterally, similar to most subsequent studies. We implanted our patients with drug-resistant chronic cluster headache unilaterally and noted a side-shift in 36% of patients. However, contralateral attacks were rare, arose in isolation or in short bouts, and were managed easily by adjustment of drug treatment.²⁴ Nonetheless, bilateral implantation should probably be preferred in the future.

The initial rationale for use of occipital nerve stimulation in headache treatment stems from findings of animal studies showing the convergence of cervical, somatic, and dural (trigeminovascular) afferents on second order nociceptors in the trigeminocervical complex.^{91,92} Clinical observations of the effectiveness of suboccipital steroid injections for prevention of several primary headaches supported the rationale.^{93–95}

Occipital nerve stimulation might, however, act via a non-specific modulatory effect on pain-control systems. Observations in 36% of patients with drug-resistant chronic cluster headaches treated with occipital nerve stimulation indicate that pain attacks might be greatly reduced or eliminated whereas non-painful autonomic attacks persist,²⁴ suggesting an underlying attack generator is still active. In line with this hypothesis, we did an ¹⁸F-DG-PET study of ten patients with drug-resistant chronic cluster headache who were treated with occipital nerve stimulation.⁹⁶ Pretreatment hypermetabolism in several areas of the pain matrix returned to normal after 3–6 months, whereas hypermetabolism in the ipsilateral hypothalamus persisted unchanged. Furthermore, persistent hyperactivity in the dorsal rostral pons was also reported with H₂¹⁵O PET in patients with chronic migraine treated with occipital nerve stimulation.⁷⁵ Although time to relief with occipital nerve stimulation could take several months, attacks usually recur shortly after stimulator arrest, both in chronic migraine and chronic cluster headache,^{24,66,75} arguing against simple natural evolution of the disorder or a placebo effect. Nonetheless, a placebo effect must be excluded with well-designed trials, which are difficult to blind because of occipital nerve stimulation-induced paraesthesias. Most available or ongoing studies use

infrathreshold stimulation intensities as a control, but masking of patients who perceive no or minimum sensations might be difficult to maintain in the long term.

Sphenopalatine ganglion stimulation

The sphenopalatine ganglion is an extracranial autonomic ganglion lying in the pterygopalatine fossa. It has connections notably with the trigeminovascular system, the superior salivary nucleus, and the hypothalamus. The sphenopalatine ganglion has been targeted over the years by various lesional techniques (eg, anaesthetic blocks, radiosurgery, and gamma knife), particularly to treat cluster headache. Alcohol injections were reported to be effective in 85% of patients in an open study.⁹⁷

In two proof-of-concept studies, high frequency electrical stimulation of the sphenopalatine ganglion with a removable electrode was effective in stopping both cluster headache⁹⁸ and migraine⁹⁹ attacks. In cluster headache,⁹⁸ complete resolution of pain was obtained in 11 of 18 attacks within 1–3 min of stimulation and in four other attacks there was 50% relief. In migraine,⁹⁹ sphenopalatine ganglion stimulation suppressed or relieved headache in five of ten stimulated patients.

A microstimulator can now be implanted permanently into the pterygopalatine fossa and activated on demand by a remote controller positioned over the cheek. A multicentre sham-controlled trial is underway to study the effect of such a stimulation system in patients with drug-resistant chronic cluster headache.¹⁰⁰ Preliminary interim results of the non-randomised phase in 20 patients suggest a rapid abortive action on the cluster attack and a possible preventive effect. A similar trial is planned in individuals with frequent refractory migraine.¹⁰¹

Surgery-related local adverse events (eg, swelling, oedema, and sensory disturbances) seem to be as prevalent as in other maxillofacial surgical procedures. The anatomy of the pterygomaxillary fissure through which the microstimulator is implanted and surgical expertise seem to be important factors affecting outcome. Three patients had to undergo explantation because of lead migration or misplacement.¹⁰⁰

Other types of nerve stimulation

Vagus nerve stimulation has been used in several disorders such as epilepsy, depression, heart failure, and systemic inflammatory diseases. Only observational case studies or retrospective surveys of patients with epilepsy treated with vagus nerve stimulation are available for headache. In a retrospective survey,¹⁰² three of four patients reported a substantial improvement of migraine frequency. In another retrospective study,¹⁰³ eight of ten patients with migraine had a 50% or more reduction in headache frequency in the 6 months after treatment initiation, compared with the 3-month baseline period. A substantial reduction in headache frequency was also noted in two people with refractory epilepsy, one with

chronic tension-type headache¹⁰⁴ and one with migraine.¹⁰⁵ Mausekopp and colleagues¹⁰⁶ noted a good response to vagus nerve stimulation in two of four patients with chronic migraine and in two patients with chronic cluster headache. In another study, two of four patients with refractory chronic migraine improved significantly with vagus nerve stimulation.¹⁰⁷ Devices claiming to stimulate the vagus nerve transcutaneously in the neck or outer ear are likely to be tested in headache patients in the near future. The mode of action of vagus nerve stimulation remains elusive. In epilepsy, the technique is known to modulate several cortical and subcortical structures and its effect on nociception is well studied in animals and, to some extent, man.¹⁰⁸

Bilateral auriculotemporal nerve stimulation was done in one patient with chronic migraine. Pain fell from 8–9 to 5 on a 10-point visual analogue scale.¹⁰⁹

Percutaneous supraorbital nerve stimulation produced almost complete resolution of symptoms in a patient with refractory chronic cluster headache.¹¹⁰ In a retrospective study of five patients with refractory trigeminal autonomic cephalalgias, an implantable supraorbital and supratrochlear neuromodulation system led to a substantial fall in pain intensity.¹¹¹ Percutaneous supraorbital nerve stimulation has been used in combination with occipital nerve stimulation in several studies by Reed and colleagues (table 5).^{81,85} In a retrospective series of 44 individuals with chronic migraine (mean follow-up 13 months), the frequency of severe headaches decreased by 81% and half the patients had nearly complete disappearance of headaches.⁸¹ The same double stimulation applied to 11 young people (age 12–17 years) with refractory headaches resulted in a pain-free state in 60% and all could return to normal schooling.⁸³ In a pilot study of ten patients, a novel transcutaneous supraorbital electrostimulation device (Cefaly, STX-Med, Liège, Belgium) was as effective as an acute antimigraine treatment in 43% of attacks (13% pain-free) and had a somewhat preventive effect after daily treatment for 3 months.¹¹²

Future prospects

Neurostimulation is of growing interest for treatment of headache. Progress has been driven by technological advances and the relative absence of effective and well tolerated drugs for prevention of primary headaches. About 1200 headache patients worldwide have been treated with neurostimulation, and their outcome is globally favourable (table 2). However, most studies discussed here were open trials without a sham arm and were typically underpowered. Therefore, a placebo effect cannot be ruled out fully. Moreover, better selection of patients is needed, because many trials reviewed included patients with combined headaches or with medication overuse headache.

Momentum has switched from use of invasive and non-riskless methods such as deep brain stimulation for rare

Search strategy and selection criteria

Articles selected for this Review were identified by a PubMed search with the keywords “headache”, “occipital nerve stimulation”, “deep brain stimulation”, “vagal nerve stimulation”, “supraorbital nerve stimulation”, “sphenopalatine ganglion stimulation”, “magnetic stimulation”, “direct current stimulation”, and “peripheral nerve stimulation”. We did not use the term “neurostimulation” alone because it missed some important studies, so we preferred to do several focused searches. Only articles available in English were selected. No time limit was applied, and the search was done in April, 2012. Additional articles and abstracts were selected from reference lists and from abstract books of the latest headache congresses. We only selected original trials, case reports, and physiopathological studies.

and very disabling disorders (eg, drug-refractory chronic cluster headache) to minimally invasive or non-invasive techniques that can be justified ethically in less disabling but more prevalent disorders (eg, episodic migraine). Almost no data are available for neurostimulation in tension-type headache, with the exception of an Iranian study of transcutaneous electrical nerve stimulation.¹¹³ Tension-type headache should receive attention in future studies. The response rate for non-invasive neurostimulation techniques is not superior to that of the most effective preventive drug treatment. Neurostimulation treatments, even if non-invasive, should be initiated by trained practitioners in specialist headache centres.

Except for devices used in transcranial direct current stimulation, most neurostimulation methods are fairly expensive because they are the product of intense engineering and biotechnology research. Besides proving or confirming their effectiveness and safety in randomised controlled trials, the challenge for neurostimulation techniques will be in future years to convince policy makers that they could be advantageous from both a pharmacological and an economical perspective. To some extent, a study by Leone and colleagues¹¹⁴ assessed these factors in posterior hypothalamic deep brain stimulation, which was estimated to reduce direct costs by €2 848 125 in a cohort of 19 patients with drug-resistant chronic cluster headache.¹¹⁴

Further research is needed to disentangle the mechanisms of action of neurostimulation techniques, so we can optimise devices and stimulation protocols. Depending on the neurostimulation type, time to clinically significant improvement can vary from several weeks to months, but rarely days, which suggests slow neuromodulatory processes are in play, probably at several levels of the nervous system. By contrast, headache recurrence when stimulation is stopped is usually quick. This clinical observation has no robust pathophysiological explanation, except that neurostimulation

treatments are possibly symptomatic and do not act on headache generators.

Targeting of headache subtypes might increase therapeutic effectiveness, and studies of neurostimulation effects could shed light on headache pathophysiology. In a functional MRI study,⁵⁹ anodal transcranial direct current stimulation over the primary motor cortex was able to ameliorate thalamocortical connectivity. Since a thalamocortical dysrhythmia possibly caused interictal hyper-responsivity of the visual cortex in migraine,⁵¹ this finding provides a rationale for use of anodal rather than cathodal transcranial direct current stimulation in preventive trials.

Contributors

DM did the literature search, wrote the Review, and designed the tables. JS wrote the Review.

Conflicts of interest

JS is a consultant for ATI (Redwood, CA, USA) and STX-Med (Liège, Belgium), is an advisory board member for St Jude Medical (St Paul, MN, USA) and ATI, and has received research grants from STX-Med, Medtronic (Minneapolis, MN, USA), and Cyberonics (Houston, TX, USA). DM declares no conflicts of interest.

Acknowledgments

This work was supported by the research convention 3.4.650.09 from the National Fund for Scientific Research, Belgium (JS) and by research grants from the Faculty of Medicine, University of Liège. We thank Malek Tebache and Victor De Pasqua for their contributions to the figure.

References

- 1 Stovner L, Hagen K, Jensen R, et al. The global burden of headache: a documentation of headache prevalence and disability worldwide. *Cephalalgia* 2007; **27**: 193–210.
- 2 Headache classification subcommittee of the International Headache Society. The International Classification of Headache Disorders, 2nd edn. *Cephalalgia* 2004; **24** (suppl 1): 9–160.
- 3 Fumal A, Schoenen J. Current migraine management: patient acceptability and future approaches. *Neuropsychiatric Dis Treat* 2008; **4**: 1043–57.
- 4 Goadsby PJ, Schoenen J, Ferrari MD, Silberstein SD, Dodick D. Towards a definition of intractable headache for use in clinical practice and trials. *Cephalalgia* 2006; **26**: 1168–70.
- 5 Nguyen JP, Nizard J, Keravel Y, Lefaucheur JP. Invasive brain stimulation for the treatment of neuropathic pain. *Nat Rev Neurol* 2011; **7**: 699–709.
- 6 May A, Bahra A, Büchel C, Frackowiak RSJ, Goadsby PJ. Hypothalamic activation in cluster headache attacks. *Lancet* 1998; **352**: 275–78.
- 7 May A, Ashburner J, Büchel C, et al. Correlation between structural and functional changes in brain in an idiopathic headache syndrome. *Nat Med* 1999; **5**: 836–38.
- 8 Leone M, Franzini A, Bussone G. Stereotactic stimulation of posterior hypothalamic gray matter in a patient with intractable cluster headache. *N Engl J Med* 2001; **345**: 1428–29.
- 9 Schoenen J, Di Clemente L, Vandenheede M, et al. Hypothalamic stimulation in chronic cluster headache: a pilot study of efficacy and mode of action. *Brain* 2005; **128**: 940–47.
- 10 D’Andrea G, Nordera G, Piacentino M. Effectiveness of hypothalamic stimulation in two patients affected by intractable chronic cluster headache. *Neurology* 2006; **66** (suppl 2): A140 (abstr).
- 11 Leone M, Franzini A, Broggi G, Bussone G. Hypothalamic stimulation for intractable cluster headache: long-term experience. *Neurology* 2006; **67**: 150–52.
- 12 Benabid A, Seigneuret E, Torres N. Intraventricular stimulation for targets close to the midline: periaqueductal gray, posterior hypothalamus, anterior hypothalamus, subcommissural structures. *Acta Neurochir (Wien)* 2006; **148**: 1–64 (abstr).
- 13 Starr PA, Barbaro NM, Raskin NH, Ostrem JL. Chronic stimulation of the posterior hypothalamic region for cluster headache: technique and 1-year results in four patients. *J Neurosurg* 2007; **106**: 999–1005.

- 14 Owen SL, Green AL, Davies P, et al. Connectivity of an effective hypothalamic surgical target for cluster headache. *J Clin Neurosci* 2007; **14**: 955–60.
- 15 Black D, Bartleson J, Torgrimson S, Davis D. Two cases of chronic cluster headache treated successfully with hypothalamic deep brain stimulation. *Neurology* 2007; P07.065 (abstr).
- 16 Mateos V, Seijo F, Lozano B, et al. E. Deep brain stimulation in chronic refractory headaches: first national cases. *Neurologia* 2007; **22**: 96 (abstr).
- 17 Piacentino M, Gazzola L, Zambon G, Volpin L. Deep brain stimulation in cluster headache. In: Proceedings of the 59th annual meeting of the German Society of Neurosurgery (DGNC), 3rd joint meeting with the Italian Neurosurgical Society (SINCh). Wuerzburg, Germany; June 1–4, 2008. Düsseldorf: German Medical Science Publishing House, 2008: Doc P 094 (abstr).
- 18 Bartsch T, Pinsker MO, Rasche D, et al. Hypothalamic deep brain stimulation for cluster headache: experience from a new multicase series. *Cephalalgia* 2008; **28**: 285–95.
- 19 Bartsch T, Paemeleire K, Goadsby PJ. Neurostimulation approaches to primary headache disorders. *Curr Opin Neurol* 2009; **22**: 262–68.
- 20 Fontaine D, Lazorthes Y, Mertens P, et al. Safety and efficacy of deep brain stimulation in refractory cluster headache: a randomized placebo-controlled double-blind trial followed by a 1-year open extension. *J Headache Pain* 2010; **11**: 23–31.
- 21 Hidding U, May A. Mere surgery will not cure cluster headache: implications for neurostimulation. *Cephalalgia* 2011; **31**: 112–15.
- 22 Seijo F, Saiz A, Lozano B, et al. Neuromodulation of the posterolateral hypothalamus for the treatment of chronic refractory cluster headache: experience in five patients with a modified anatomical target. *Cephalalgia* 2011; **31**: 1634–41.
- 23 Magis D, Allena M, Bolla M, De Pasqua V, Remacle J-M, Schoenen J. Occipital nerve stimulation for drug-resistant chronic cluster headache: a prospective pilot study. *Lancet Neurol* 2007; **6**: 314–21.
- 24 Magis D, Gerardy PY, Remacle JM, Schoenen J. Sustained effectiveness of occipital nerve stimulation in drug-resistant chronic cluster headache. *Headache* 2011; **51**: 1191–201.
- 25 Leone M, Franzini A, D'Andrea G, Broggi G, Casucci G, Bussone G. Deep brain stimulation to relieve drug-resistant SUNCT. *Ann Neurol* 2005; **57**: 924–27.
- 26 Lyons MK, Dodick DW, Evidente VG. Responsiveness of short-lasting unilateral neuralgiform headache with conjunctival injection and tearing to hypothalamic deep brain stimulation. *J Neurosurg* 2009; **110**: 279–81.
- 27 Bartsch T, Falk D, Knudsen K, et al. Deep brain stimulation of the posterior hypothalamic area in intractable short-lasting unilateral neuralgiform headache with conjunctival injection and tearing (SUNCT). *Cephalalgia* 2011; **31**: 1405–08.
- 28 Walcott BP, Bamber NI, Anderson DE. Successful treatment of chronic paroxysmal hemicrania with posterior hypothalamic stimulation: technical case report. *Neurosurgery* 2009; **65**: E997.
- 29 Leone M, Franzini A, Broggi G, Mea E, Cecchini AP, Bussone G. Acute hypothalamic stimulation and ongoing cluster headache attacks. *Neurology* 2006; **67**: 1844–45.
- 30 Maniyar FH, Starr P, Goadsby PJ. Paroxysmal sneezing after hypothalamic deep brain stimulation for cluster headache. *Cephalalgia* 2012; published online April 23. DOI:10.1177/0333102412442412.
- 31 Vetrugno R, Pierangeli G, Leone M, et al. Effect on sleep of posterior hypothalamic stimulation in cluster headache. *Headache* 2007; **47**: 1085–90.
- 32 Vigneri S, Guaraldi P, Calandra-Buonaura G, et al. Switching on the deep brain stimulation: effects on cardiovascular regulation and respiration. *Auton Neurosci* 2012; **166**: 81–84.
- 33 Sani S, Shimamoto S, Turner RS, Levesque N, Starr PA. Microelectrode recording in the posterior hypothalamic region in humans. *Neurosurgery* 2009; **64** (suppl 3): 161–67.
- 34 Brittain JS, Green AL, Jenkinson N, et al. Local field potentials reveal a distinctive neural signature of cluster headache in the hypothalamus. *Cephalalgia* 2009; **29**: 1165–73.
- 35 Fontaine D, Lanteri-Minet M, Ouchchane L, et al. Anatomical location of effective deep brain stimulation electrodes in chronic cluster headache. *Brain* 2010; **133**: 1214–23.
- 36 May A, Leone M, Boecker H, et al. Hypothalamic deep brain stimulation in positron emission tomography. *J Neurosci* 2006; **26**: 3589–93.
- 37 Jurgens TP, Leone M, Proietti-Cecchini A, et al. Hypothalamic deep-brain stimulation modulates thermal sensitivity and pain thresholds in cluster headache. *Pain* 2009; **146**: 84–90.
- 38 Passard A, Attal N, Benadhira R, et al. Effects of unilateral repetitive transcranial magnetic stimulation of the motor cortex on chronic widespread pain in fibromyalgia. *Brain* 2007; **130**: 2661–70.
- 39 Bohotin V, Fumal A, Vandenheede M, et al. Effects of repetitive transcranial magnetic stimulation on visual evoked potentials in migraine. *Brain* 2002; **125**: 912–22.
- 40 Fumal A, Coppola G, Bohotin V, et al. Induction of long-lasting changes of visual cortex excitability by five daily sessions of repetitive transcranial magnetic stimulation (rTMS) in healthy volunteers and migraine patients. *Cephalalgia* 2006; **26**: 143–49.
- 41 Aurora SK, Ahmad BK, Welch KM, Bhardhwaj P, Ramadan NM. Transcranial magnetic stimulation confirms hyperexcitability of occipital cortex in migraine. *Neurology* 1998; **50**: 1111–14.
- 42 Chen R, Classen J, Gerloff C, et al. Depression of motor cortex excitability by low-frequency transcranial magnetic stimulation. *Neurology* 1997; **48**: 1398–403.
- 43 Pascual-Leone A, Valls-Sole J, Wassermann EM, Hallett M. Responses to rapid-rate transcranial magnetic stimulation of the human motor cortex. *Brain* 1994; **117**: 847–58.
- 44 Holland P, Schembri CT, Frederick JP, Goadsby P. Transcranial magnetic stimulation for the treatment of migraine aura? *Cephalalgia* 2009; **29** (suppl 1): 22 (abstr).
- 45 Clarke BM, Upton AR, Kamath MV, Al-Harbi T, Castellanos CM. Transcranial magnetic stimulation for migraine: clinical effects. *J Headache Pain* 2006; **7**: 341–46.
- 46 Lipton RB, Dodick DW, Silberstein SD, et al. Single-pulse transcranial magnetic stimulation for acute treatment of migraine with aura: a randomised, double-blind, parallel-group, sham-controlled trial. *Lancet Neurol* 2010; **9**: 373–80.
- 47 Brighina F, Piazza A, Vitello G, et al. rTMS of the prefrontal cortex in the treatment of chronic migraine: a pilot study. *J Neurol Sci* 2004; **227**: 67–71.
- 48 Conforto A, Goncalves A, Mercante J, et al. Effects of repetitive transcranial magnetic stimulation in chronic migraine: a pilot study. *Cephalalgia* 2011; **31** (suppl 1): 94.
- 49 Teepker M, Hotzel J, Timmesfeld N, et al. Low-frequency rTMS of the vertex in the prophylactic treatment of migraine. *Cephalalgia* 2010; **30**: 137–44.
- 50 Silvanto J, Pascual-Leone A. State-dependency of transcranial magnetic stimulation. *Brain Topogr* 2008; **21**: 1–10.
- 51 Coppola G, Pierelli F, Schoenen J. Is the cerebral cortex hyperexcitable or hyperresponsive in migraine? *Cephalalgia* 2007; **27**: 1427–39.
- 52 Garcia JO, Grossman ED, Srinivasan R. Evoked potentials in large-scale cortical networks elicited by TMS of the visual cortex. *J Neurophysiol* 2011; **106**: 1734–46.
- 53 Antal A, Terney D, Kuhl S, Paulus W. Anodal transcranial direct current stimulation of the motor cortex ameliorates chronic pain and reduces short intracortical inhibition. *J Pain Symptom Manage* 2010; **39**: 890–903.
- 54 Odobescu S, Rotaru L, Moldovanu I, Rotaru V, Gursky N. Non-pharmacologic acute treatment of chronic migraine patients by transcranial cerebral electrical stimulation vs. placebo. *Cephalalgia* 2011; **31** (suppl 1): 101.
- 55 Antal A, Kriener N, Lang N, Boros K, Paulus W. Cathodal transcranial direct current stimulation of the visual cortex in the prophylactic treatment of migraine. *Cephalalgia* 2011; **31**: 820–28.
- 56 DaSilva AF, Mendonca ME, Zaghi S, et al. tDCS-induced analgesia and electrical fields in pain-related neural networks in chronic migraine. *Headache* 2012; published online April 18. DOI:10.1111/j.1526-4610.2012.02141.x.
- 57 Hansen N, Obermann M, Poitz F, et al. Modulation of human trigeminal and extracranial nociceptive processing by transcranial direct current stimulation of the motor cortex. *Cephalalgia* 2011; **31**: 661–70.
- 58 Keeser D, Padberg F, Reisinger E, et al. Prefrontal direct current stimulation modulates resting EEG and event-related potentials in healthy subjects: a standardized low resolution tomography (sLORETA) study. *NeuroImage* 2011; **55**: 644–57.

- 59 Polania R, Paulus W, Nitsche MA. Modulating cortico-striatal and thalamo-cortical functional connectivity with transcranial direct current stimulation. *Hum Brain Mapp* 2011; published online Sept 16. DOI:10.1002/hbm.21380.
- 60 Coppola G, Ambrosini A, Di Clemente L, et al. Interictal abnormalities of gamma band activity in visual evoked responses in migraine: an indication of thalamocortical dysrhythmia? *Cephalalgia* 2007; **27**: 1360–67.
- 61 Liebetanz D, Fregni F, Monte-Silva KK, et al. After-effects of transcranial direct current stimulation (tDCS) on cortical spreading depression. *Neurosci Lett* 2006; **398**: 85–90.
- 62 Melzack R, Wall PD. Pain mechanisms: a new theory. *Science* 1965; **150**: 971–79.
- 63 DeSantana JM, Da Silva LF, De Resende MA, Sluka KA. Transcutaneous electrical nerve stimulation at both high and low frequencies activates ventrolateral periaqueductal grey to decrease mechanical hyperalgesia in arthritic rats. *Neuroscience* 2009; **163**: 1233–41.
- 64 Weiner RL, Reed KL. Peripheral neurostimulation for control of intractable occipital neuralgia. *Neuromodulation* 1999; **2**: 217–22.
- 65 Burns B, Watkins L, Goadsby PJ. Treatment of medically intractable cluster headache by occipital nerve stimulation: long-term follow-up of eight patients. *Lancet* 2007; **369**: 1099–106.
- 66 Burns B, Watkins L, Goadsby PJ. Treatment of intractable chronic cluster headache by occipital nerve stimulation in 14 patients. *Neurology* 2009; **72**: 341–45.
- 67 Proietti Cecchini A, Mea E, Tullo V, et al. Occipital nerve stimulation in drug-resistant chronic cluster headache. *Cephalalgia* 2009; **29** (suppl 1): 150 (abstr).
- 68 Lara Lara M, Paz Solis J, Ortega-Casarubios MA, PalaoTarrero A, Heredero J, Diez-Tejedor E. Occipital nerve stimulation: is peripheral approach effective in cluster headache? *Cephalalgia* 2009; **29** (suppl 1): 44 (abstr).
- 69 de Quintana-Schmidt C, Casajuana-Garreta E, Molet-Teixidó J, et al. [Stimulation of the occipital nerve in the treatment of drug-resistant cluster headache]. *Rev Neurol* 2010; **51**: 19–26 [in Spanish].
- 70 Salom JM, Lainez JM. Subcutaneous occipital nerve neurostimulation treatment for refractory headaches. *J Headache Pain* 2010; **11** (suppl 1): S148 (abstr).
- 71 Müller OM, Gaul C, Katsarava Z, Diener HC, Sure U, Gasser T. Occipital nerve stimulation for the treatment of chronic cluster headache: lessons learned from 18 months' experience. *Cen Eur Neurosurg* 2011; **72**: 84–89.
- 72 Fontaine D, Christophe Sol J, Raoul S, et al. Treatment of refractory chronic cluster headache by chronic occipital nerve stimulation. *Cephalalgia* 2011; **31**: 1101–05.
- 73 Strand NH, Trentman TL, Vargas BB, Dodick DW. Occipital nerve stimulation with the bion(R) microstimulator for the treatment of medically refractory chronic cluster headache. *Pain Physician* 2011; **14**: 435–40.
- 74 Popeney CA, Alo KM. Peripheral neurostimulation for the treatment of chronic, disabling transformed migraine. *Headache* 2003; **43**: 369–75.
- 75 Matharu MS, Bartsch T, Ward N, Frackowiak RS, Weiner R, Goadsby PJ. Central neuromodulation in chronic migraine patients with suboccipital stimulators: a PET study. *Brain* 2004; **127**: 220–30.
- 76 Schwedt TJ, Dodick DW, Hentz J, Trentman TL, Zimmerman RS. Occipital nerve stimulation for chronic headache: long-term safety and efficacy. *Cephalalgia* 2007; **27**: 153–57.
- 77 Lipton R, Goadsby P, Cady R, et al. PRISM study: occipital nerve stimulation for treatment-refractory migraine. *Cephalalgia* 2009; **29** (suppl 1): 30.
- 78 Marchioretto F, Serra G. Suboccipital neurostimulation in chronic headache: a prospective, randomized with cross over study. *J Headache Pain* 2010; **11** (suppl 1): S2 (abstr).
- 79 Saper JR, Dodick DW, Silberstein SD, McCarville S, Sun M, Goadsby PJ. Occipital nerve stimulation for the treatment of intractable chronic migraine headache: ONSTIM feasibility study. *Cephalalgia* 2011; **31**: 271–85.
- 80 Silberstein S, Dodick D, Saper J, et al. The safety and efficacy of occipital nerve stimulation for the management of chronic migraine. *Cephalalgia* 2011; **31** (suppl 1): 117 (abstr).
- 81 Reed KL, Will KR, Chapman J, Richter E. Combined occipital and supraorbital neurostimulation for chronic migraine headaches: an extended case series. *Cephalalgia* 2011; **31** (suppl 1): 98 (abstr).
- 82 Narouze S, Saad R, Kapural L. Occipital nerve stimulation with self-anchoring leads for the management of refractory chronic migraine. *Cephalalgia* 2011; **31** (suppl 1): 85 (abstr).
- 83 Linder S, Reed K. Combined occipital nerve/supraorbital nerve stimulation for treatment of refractory headaches: initial adolescent experience. *Cephalalgia* 2011; **31** (suppl 1): 171 (abstr).
- 84 Paemeleire K, Van Buyten JP, Van Buynder M, et al. Phenotype of patients responsive to occipital nerve stimulation for refractory head pain. *Cephalalgia* 2010; **30**: 662–73.
- 85 Reed KL, Black SB, Banta CJ II, Will KR. Combined occipital and supraorbital neurostimulation for the treatment of chronic migraine headaches: initial experience. *Cephalalgia* 2010; **30**: 260–71.
- 86 Burns B, Watkins L, Goadsby PJ. Treatment of hemicrania continua by occipital nerve stimulation with a bion device: long-term follow-up of a crossover study. *Lancet Neurol* 2008; **7**: 1001–12.
- 87 Marin JC, Goadsby P. Response of SUNCT (short-lasting unilateral neuralgiform headaches with conjunctival injection and tearing), SUNA (short-lasting unilateral neuralgiform headaches with autonomic symptoms) and primary stabbing headaches to occipital nerve stimulation (ONS). *Neurology* 2010; **74** (suppl 2): P04.006 (abstr).
- 88 Shanahan P, Watkins L, Matharu M. Treatment of medically intractable short-lasting unilateral neuralgiform headache attacks with conjunctival injection and tearing (SUNCT) and short-lasting unilateral neuralgiform headache attacks with autonomic symptoms (SUNA) with occipital nerve stimulation (ONS) in 6 patients. *Cephalalgia* 2009; **29** (suppl 1): 150 (abstr).
- 89 Marin JC, Goadsby P. Response of primary stabbing headache to occipital nerve stimulation (ONS). *Cephalalgia* 2009; **29** (suppl 1): 110 (abstr).
- 90 Wolter T, Kaube H, Mohadjer M. High cervical epidural neurostimulation for cluster headache: case report and review of the literature. *Cephalalgia* 2008; **28**: 1091–94.
- 91 Bartsch T, Goadsby PJ. Stimulation of the greater occipital nerve induces increased central excitability of dural afferent input. *Brain* 2002; **125**: 1496–509.
- 92 Bartsch T, Goadsby PJ. Increased responses in trigeminocervical nociceptive neurons to cervical input after stimulation of the dura mater. *Brain* 2003; **126**: 1801–13.
- 93 Anthony M. Headache and the greater occipital nerve. *Clin Neurol Neurosurg* 1992; **94**: 297–301.
- 94 Ambrosini A, Vandenheede M, Rossi P, et al. Suboccipital injection with a mixture of rapid- and long-acting steroids in cluster headache: a double-blind placebo-controlled study. *Pain* 2005; **118**: 92–96.
- 95 Afridi SK, Shields KG, Bhola R, Goadsby PJ. Greater occipital nerve injection in primary headache syndromes: prolonged effects from a single injection. *Pain* 2006; **122**: 126–29.
- 96 Magis D, Bruno MA, Fumal A, et al. Central modulation in cluster headache patients treated with occipital nerve stimulation: an FDG-PET study. *BMC Neurol* 2011; **11**: 25.
- 97 Devoghel JC. Cluster headache and sphenopalatine block. *Acta Anaesthesiol Belg* 1981; **32**: 101–07.
- 98 Ansarinia M, Rezaei A, Tepper SJ, et al. Electrical stimulation of sphenopalatine ganglion for acute treatment of cluster headaches. *Headache* 2010; **50**: 1164–74.
- 99 Tepper SJ, Rezaei A, Narouze S, Steiner C, Mohajer P, Ansarinia M. Acute treatment of intractable migraine with sphenopalatine ganglion electrical stimulation. *Headache* 2009; **49**: 983–89.
- 100 Lainez M, Jensen R, May A, et al. Pathway CH-1 study: sphenopalatine ganglion (SPG) stimulation for acute treatment of chronic cluster headache (CCH): initial experience. *Neurology* 2012; **78**: S36.002 (abstr).
- 101 Paemeleire K, Goodman AM. Results of a patient survey for an implantable neurostimulator to treat migraine headaches. *J Headache Pain* 2012; **13**: 239–41.
- 102 Hord ED, Evans MS, Mueed S, Adamolekun B, Naritoku DK. The effect of vagus nerve stimulation on migraines. *J Pain* 2003; **4**: 530–34.
- 103 Lenaerts ME, Oommen KJ, Couch JR, Skaggs V. Can vagus nerve stimulation help migraine? *Cephalalgia* 2008; **28**: 392–95.

- 104 Kirchner A, Birklein F, Stefan H, Handwerker HO. Left vagus nerve stimulation suppresses experimentally induced pain. *Neurology* 2000; **55**: 1167–71.
- 105 Sadler RM, Purdy RA, Rahey S. Vagal nerve stimulation aborts migraine in patient with intractable epilepsy. *Cephalalgia* 2002; **22**: 482–84.
- 106 Mauskop A. Vagus nerve stimulation relieves chronic refractory migraine and cluster headaches. *Cephalalgia* 2005; **25**: 82–86.
- 107 Cecchini AP, Mea E, Tullo V, et al. Vagus nerve stimulation in drug-resistant daily chronic migraine with depression: preliminary data. *Neurol Sci* 2009; **30** (suppl 1): S101–04.
- 108 Multon S, Schoenen J. Pain control by vagus nerve stimulation: from animal to man...and back. *Acta Neurol Belgica* 2005; **105**: 62–67.
- 109 Simopoulos T, Bajwa Z, Lantz G, Lee S, Burstein R. Implanted auriculotemporal nerve stimulator for the treatment of refractory chronic migraine. *Headache* 2010; **50**: 1064–69.
- 110 Narouze SN, Kapural L. Supraorbital nerve electric stimulation for the treatment of intractable chronic cluster headache: a case report. *Headache* 2007; **47**: 1100–02.
- 111 Vaisman J, Markley H, Ordia J, Deer T. The treatment of medically intractable trigeminal autonomic cephalalgia with supraorbital/supratrochlear stimulation: a retrospective case series. *Neuromodulation* 2012; published online May 2. DOI:10.1111/j.1525-1403.2012.00455.x.
- 112 Gérardy PY, Fabry D, Fumal A, Schoenen J. A pilot study on supra-orbital surface electrotherapy in migraine. *Cephalalgia* 2009; **29**: 134 (abstr).
- 113 Mousavi SA, Mirbod SM, Khorvash F. Comparison between efficacy of imipramine and transcutaneous electrical nerve stimulation in the prophylaxis of chronic tension-type headache: a randomized controlled clinical trial. *J Res Med Sci* 2011; **16**: 923–27.
- 114 Leone M, Franzini A, Cecchini AP, Mea E, Broggi G, Bussone G. Costs of hypothalamic stimulation in chronic drug-resistant cluster headache: preliminary data. *Neurol Sci* 2009; **30** (suppl 1): S43–47.