

## CLINICAL CASE SERIES

# The Complications of Transforaminal Lumbar Epidural Steroid Injections

Haktan Karaman, MD\* Gönül Ölmez Kavak, MD,† Adnan Tüfek, MD,† and Zeynep Baysal Yıldırım, MD†

**Study Design.** A prospective observational study.

**Objective.** In this study, we aimed to investigate the major and minor complications of transforaminal lumbar epidural steroid injections guided by fluoroscopy and the incidence of vascular penetration encountered during this procedure.

**Summary of Background Data.** Epidural steroid administration is one of the treatment options for lumbar disc hernia accompanied by radiculopathy. This method, initially applied by blind interlaminar technique, has generally been performed by fluoroscopically guided transforaminal method now. The complications of this method cause to a serious concern. The complications of this intervention have been reported by either mostly retrospective studies or case reports until now. Prospective studies with large patient series are needed to determine the types and incidences of the complications.

**Methods.** In this study carried out for more than 5 years, major and minor complications of transforaminal lumbar epidural steroid injections were investigated prospectively. All of the interventions were performed under fluoroscopic guidance by the same physician using a standardized method. A follow-up was made once in the third week. The complications encountered during the procedure and in the third week were prospectively recorded. In addition, the incidence of vascular penetration that is potentially hazardous is included in the study.

**Results.** A total of 562 patients were performed 1305 times transforaminal lumbar epidural steroid. The overall incidence of vascular penetration encountered was 7.4%. Although major complications were not seen, the total rate of all minor complications was 11.5%. Whereas all of the minor complications were transient, the most frequent minor complication was vasovagal reaction (8.7%).

**Conclusion.** On the basis of the results of this study in which only minor complications were encountered, it can be said that the frequency of major complications is pretty rare in transforaminal lumbar epidural steroid injections in expert hands and in the conditions in which safety precautions are taken.

From the \*Department of Anesthesiology, Pain Management Center and †Department of Anesthesiology, Dicle University, Diyarbakir, Turkey.

Acknowledgment date: January 21, 2010. Revision date: March 26, 2010. Accepted date: July 6, 2010.

The manuscript submitted does not contain information about medical device(s)/drug(s).

No funds were received in support of this work. No benefits in any form have been or will be received from a commercial party related directly or indirectly to the subject of this manuscript.

Address correspondence and reprint requests to Dicle Universitesi Tıp Fakültesi Anestezi A.D. 21280 Diyarbakir, Turkey; E-mail: haktan@dicle.edu.tr

DOI: 10.1097/BRS.0b013e3181f32bae

**Key words:** transforaminal, lumbar, epidural, steroid, complication.  
**Spine 2011;36:E819–E824**

Lumbar pain seen widely in the population leads to a significant morbidity and labor loss.<sup>1–3</sup> Although, most of lumbar pain episodes improve with mild bed rest, medical therapy, and physiotherapy, a part of them becomes chronic and leads to a more severe health problems. One of the most important reasons of chronic lumbar pain is lumbar disc hernia.<sup>4</sup> One of the interventional therapeutic methods except surgery for these patients diagnosed with lumbar disc hernia by the signs on clinical examination and imaging techniques is lumbar epidural steroid injection (LESI).<sup>5–8</sup> Therapeutic efficacy of LESI traditionally applied via interlaminar or caudal way has always been controversial.<sup>9</sup> Because LESI is performed by blind technique via these ways, whether an actual epidural distribution occurs is debatable. On the other hand, even if an actual epidural distribution was provided, an insufficient ventral distribution to anterior epidural region in which herniation is located has been a question.<sup>10–13</sup> Moreover, the excessive drug volume and dose given by these ways lead to an increase in systemic adverse effects.

One of the methods developed to achieve an effective treatment with lower amounts of drug is the implementation of fluoroscopically guided transforaminal LESI (TLESI).<sup>14</sup> In the studies performed, the therapeutic effect of TLESI was found to be superior to that of LESI implemented via interlaminar and caudal ways and with TLESI much less amounts of medication can be injected into anterior epidural region by fluoroscopic guidance.<sup>14–16</sup>

However, very severe major complications along with some minor complications regarding fluoroscopically guided TLESI applications were reported in the literature. Major complications include death, paraplegia resulted from the injection of the drugs especially with particles into arteria radicularia magna-Adamkiewicz artery (AKA) by mistake, discitis because of accidental puncture into disc, intravenous injection, dural sac puncture and intrathecal injection, nerve injury, and air embolism. Minor complications include spinal headache, transient nonspinal headache, transient hypotension, nausea, and vomiting.<sup>17,18</sup>

Until now, there are few studies focused only on the complications of TLESI. In a retrospective study investigating the complications of TLESI published in 2000, Botwin *et al* denoted

that they observed none of the major complications whereas the rate of total minor complications, which were transient headache, increased lumbar and leg pain, vasovagal reaction, and rash, was 9.6%.<sup>19</sup> In a retrospective study with a large series of patients published in 2006, Stalcupa *et al* investigated the complications of selective lumbar nerve blockages and the relationship between probable complications of TLESI and the positions of the tip of the needle used. This study found no association between the complications and the needle tip position, the investigators reported that they did never face with any major complication and they reported an incidence rate of 5.5% for overall minor complications.<sup>20</sup> The unique prospective study, as long as we know, investigating the complications of TLESI is a trial published by Huston *et al* in 2005. In this study, the complications because of cervical and lumbosacral selective nerve root injections was investigated prospectively. This study reported no major complication, transient minor complications, such as pain at the puncture site (17.1%), increased radicular pain (8.8%), lightheadedness (6.5%), increased spinal pain (5.1%), nausea (3.7%), nonspecific headache (1.4%), and vomiting (0.5%), were reported.<sup>21</sup> Except these studies, the complications regarding TLESI implications are mentioned in case reports in the literature.

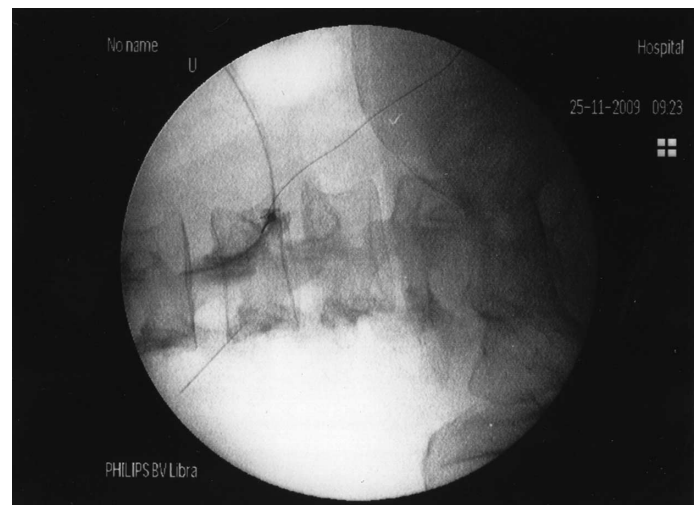
Prospective studies with large patient series are needed to determine the actual rate of the complications of TLESI that is effective in lumbar disc hernia accompanied by radicular pain and become more commonly implemented. In this study, the complications of 1305 implementation of TLESI in 562 patients in the period of more than 5 years were evaluated. The strongest point of our study is the implementation of TLESI with a standardized method applied by a single person.

## MATERIALS AND METHODS

This study is prospectively designed and investigates the major and minor complications of TLESI implemented in the patients with radiculopathy because of lumbar disc hernia referred to the pain clinic of our hospital in the period from November 2003 to December 2008 after receiving of the consent of the university hospital ethics committee. After the patients included in the study were informed about the procedure to perform in a verbal and written form, their written consents about accepting the intervention were received from all patients.

The patients not respond to the medical therapies and physiotherapy methods applied before for the complaint of lumbar and leg pain because of lumbar disc hernia were included in the study. The criteria to be included in the study were (1) to accept the procedure and the study, (2) the presence of clinical examination findings to explain low back and leg pain because of lumbar disc hernia, and (3) the presence of lumbar disc pathology determined on MRI by an experienced radiologist, corresponding with lumbar and leg pain. The criteria used for the exclusion from the study were (1) not to accept the procedure and the study, (2) previous spinal surgery history for any reason, (3) pregnancy, and (4) general conditions contraindicating to interventional methods, such as coagulopathy, sepsis, a known allergy against the drugs and contrast material to be used.

All injections were performed in the same way, as follows. After routine hemogram, biochemical and coagulation parameters of the patients were confirmed to be normal; the patients were included in the study. All of the patients to be performed TLESI were prepared according to the standard fasting protocol (6–8 hours fasting), then they were positioned on fluoroscopy table in prone position with a venous access and 0.9% NaCl infusion before the intervention. After providing standard monitoring (pulse oximetry, blood pressure, and ECG), the region to be intervened was covered according to sterility rules after cleaning with iodinated antiseptic solution. Sedation was not given routinely not to mask probable complications. In case it was necessary (excessive excitement, anxiety, *etc.*) “conscious sedation” was provided with 1–2 mg of midazolam. The intervention area was anesthetized with 0.5 mL of 1% lidocaine injected into skin and subcutaneous tissue. All TLESI interventions were performed with a 21G × 100 mm stimulation needle with blunt tip (Stimuplex® A 100, B Braun, Melsungen, Germany) and under the guidance of C-arm fluoroscopy. The target point was accessed by the subpedicular “safe triangle”<sup>22</sup> approach in oblique position. In all TLESI applications, a mixture of 80 mg triamcinolone acetonide in 0.25% bupivacaine was used. After the placement of the needle in target point, 0.5–2 mL of nonionic contrast material was injected to determine whether there was “vascular leakage or intrathecal distribution,” and after the accurate anterior epidural flow pattern was seen on oblique, anteroposterior and lateral images, totally 4 mL of the mixture was injected if TLESI was performed for a single level (Figure 1). If TLESI was performed for more than one level, 2 mL of the mixture per each level was applied (total steroid dose was kept to be constant, for example if it was applied for four levels, a total of 8 mL of the 80 mg triamcinolone acetonide in 0.25% bupivacaine mixture). In case of vascular leakage, the site of the needle was slightly repositioned and recontrolled by contrast material. If the vascular leakage persisted, the procedure was cancelled at that level. If the intervention was made for more than one level, the erroneous injection



**Figure 1.** Accurate epidural distribution of contrast material on oblique image.

of the residual mixture into subsequent level was avoided by flushing the needle with sterile isotonic after each level. The patients rested on the intervention table for 5 minutes, were transported to the recovery room in which they stayed for 2 hours, if no complication developed. The complications occurred during the procedure were recorded by the practitioner physician. Although vascular penetrations are not a complication, it is accepted to be a potential complication because intravascular drug injection may result in irreparable outcomes, therefore all vascular penetration data were included in the analyses. In the resting room, the patients were observed up by an experienced clinical nurse under the supervision of a physician and asked for earlier complications. All the data obtained from the patients were recorded on the patients' charts. The patients discharged from the hospital were asked to refer immediately to our institute in case an unexpected situation occurred. If there was not any extraordinary situation, they were controlled once after 3 weeks. On the control day, the patients were asked for the probable postinterventional complications as well as the therapeutic effects of TLESI and the findings obtained were also recorded on the patients' charts. Moreover, age, gender, the level and side of the lumbar disc hernia of the patients were collected. A physician not included in the study elaborated all the data for analyses.

The statistical analysis was made with  $\chi^2$  test. If  $P$  value was below 0.05, it was accepted to be statistically significant.

## RESULTS

Totally 1335 TLESI were performed in 580 patients included in the study. However, 18 patients (30 TLESI) who did not come to control in the third week were excluded from analyses. The demographical characters of these patients were not different from the study group. Although these patients were excluded from the study, none of them developed any major complication during and shortly after the procedure and no feedback of the patients were received about any further complication. Therefore, the remaining 562 patients after excluding these patients lost in the follow-up period were evaluated for complications.

Of 562 patients included in the analyses, 52.3% (n:294) was woman whereas 47.7% (n:268) was man. Total 1305 TLESI were performed in 562 patients as 754 interventions for 966 levels. The mean of disc hernia per patient was 1.7 and TLESI was repeated a mean of 1.3 times per patient. Including repeated TLESI, each patient was performed TLESI with a mean of 2.3 times (Table 1). Whereas TLESI was performed for maximum five levels (range 1–5) in a single patient in a single session, the maximum repetition number was 4 (range 1–4).

Of the hernias, 30.3% was placed in L5-S1 level, 45.6% in L4-L5 level, and 17.1% in L3-L4 level and the remaining 7%

**TABLE 1. The Characteristics of the Patients**

| Total   | 562                           |
|---|-------------------------------|
| Women, n (%)                                    | 294 (52.3%)                   |
| Men, n (%)                                      | 268 (47.7%)                   |
| Age   |                               |
| Women (mean $\pm$ SD)                           | 43.9 $\pm$ 13.4 range (16–94) |
| Men (mean $\pm$ SD)                             | 41.6 $\pm$ 12.9 range (16–91) |
| Mean no. LDH (per patient)                      | 1.7                           |
| Mean no. the repetitions of TLESI (per patient) | 1.3                           |
| Mean no. TLESI applications (per patient)       | 2.3                           |
| Side  |                               |
| Left  | 287 (51.1%)                   |
| Right   | 254 (45.2%)                   |
| Bilateral                                       | 21 (3.7%)                     |

distributed in other levels. Hence, totally 93% of the hernias were placed in the interval of L3-S1 (Table 2).

Vascular penetration was encountered in totally 97 times, in overall TLESI interventions. The most common vascular penetration was seen in the levels of L2-L3 (13.3%) and L1-L2 (10%). In L3-S1 interval generating 93% of the hernias, vascular penetration incidence was 7.2%. When all levels were considered, the total rate of vascular penetration was 7.4% (Table 3). No statistically significant difference was found between the findings and age, gender ( $\chi^2 = 4.200$ ,  $P = 0.521$ ;  $\chi^2 = 2.302$ ,  $P = 0.129$ , respectively).

The most frequently encountered complication was vasovagal reaction observed in 8.7% of the patients. It was characterized with hypotension, nausea, and dizziness. The mean age of the patients developed vasovagal reaction was 39.3. All vasovagal reactions were benign in character and only five patients were given 5 mg intravenous ephedrine once each. Hence, only 0.9% of the patients developed hypotension-required ephedrine. The rest of the patients were recovered with fluid support and trendelenburg positioning within maximum 30 minutes. No statistically significant difference was found between the findings and age, gender ( $\chi^2 = 8.634$ ,  $P = 0.125$ ;  $\chi^2 = 0.036$ ,  $P = 0.850$ , respectively).

A transient erectile dysfunction was observed in five (1.9%) of the patients. These patients developed erectile dysfunction recovered within 1 month without any treatment after confirmation by urologic consultation revealed no organic pathology.

**TABLE 2. The Levels of Hernias**

|   | T11–T12 | T12-L1 | L1-L2 | L2-L3 | L3-L4 | L4-L5 | L5-S1 | Total  |
|---|---------|--------|-------|-------|-------|-------|-------|--------|
| n | 1       | 10     | 23    | 34    | 165   | 440   | 293   | 966    |
| % | 0.1%    | 1.0%   | 2.4%  | 3.5%  | 17.1% | 45.6% | 30.3% | 100.0% |



**TABLE 3. The Distribution of Vascular Penetrations by Levels**

|                                      | T11-T12 | T12-L1 | L1-L2 | L2-L3 | L3-L4 | L4-L5 | L5-S1 | Total |
|--------------------------------------|---------|--------|-------|-------|-------|-------|-------|-------|
| The distribution of TLESIs performed | 1       | 13     | 30    | 45    | 226   | 596   | 394   | 1305  |
| Vascular penetration                 | 0       | 1      | 3     | 6     | 16    | 41    | 30    | 97    |
| %                                    | 0.0%    | 7.7%   | 10.0% | 13.3% | 7.1%  | 6.9%  | 7.6%  | 7.4%  |

Facial flushing developed in five (0.9%) patients. These patients, in whom flushing was seen, have an atopic structure. They recovered within 1 week without any treatment.

All of these complications mentioned above were accepted to be minor complications and their overall incidence was 11.5%. Except these ones, no other major–minor complication was observed. Furthermore, no adverse effects because of steroids were seen despite the fact that some patients were performed four distinct sessions of TLESI with intervals.

## DISCUSSION

Intervertebral foramen has a complex structure. There are spinal nerves, dorsal root ganglion, segmental spinal artery, communicant veins, sinuvertebral nerves, and transforaminal ligaments inside the foramina.<sup>23,24</sup> Segmental arteries responsible for feeding of medulla spinalis are branches of intercostal and lumbar arteries diverged from aorta. Segmental arteries are divided into anterior and posterior radicular arteries when they pass throughout the foramina. Posterior radicular arteries transform into radiculopial arteries, which form anastomosis with posterior spinal artery that feed posterior part of medulla spinalis. Anterior radicular arteries transform into radiculomedullary arteries and they form anastomosis with anterior spinal artery that provides blood supply to anterior part of medulla spinalis. The most important one of these vascular structures feeding medulla spinalis is arteria radicularia magna—AKA. AKA is the largest radiculomedullary artery that forms anastomosis with anterior spinal artery. AKA itself is the most important artery feeding anterior part of inferior thoracic and lumbar medulla spinalis. It enters into spinal canal throughout the left intervertebral foramen in the rate of 69% to 85%.<sup>25</sup> Although the site of entry can be any foramen between T5-S1, in the rate of 85% it is between T9-L2 levels.<sup>26</sup> Any injury of AKA occurred during the intervention causes to the necrosis of inferior medulla spinalis and consequently paraplegia. Vascular structures located within foramen can be penetrated and even drug injection can be occurred by TLESI intervention. Intravenous injection causes to the emergence of systemic effects rather than local effects of the drugs used. The severity of these effects varies because of the amount of the drugs used, especially local anesthetics. However, a significant effect does not occur because the doses given with TLESI are usually lower. This feature is not valid for AKA. With the injury of AKA because of the needle used during TLESI application or the injection of drug mixture with particles (e.g., triamcinolone acetonide) into AKA, blood supply of medulla spinalis is interrupted and the necrosis of medulla spinalis will be inevitable.<sup>26,27</sup> Therefore, a special care should be taken in

TLESI interventions, especially when it is performed for left side and inferior thoracic–superior lumbar levels. However, it must be remembered that AKA is faced in the right and in inferior lumbar, even S1 level. In TLESI application, the drug should be given after confirming an accurate epidural distribution without vascular uptake by contrast material. Although vascular penetration was seen in the overall rate of 7.4% in our study, none of our patients developed paraplegia as well as systemic toxic effect of local anesthetic. Furman *et al*<sup>28</sup> and Smuck *et al*,<sup>29</sup> in their distinct prospective studies investigating intravascular penetration rates encountered during TLESI applications, reported the mean intravascular penetration incidence to be 8.1% and 13.1%, respectively. In our study, the mean vascular penetration rate in the levels of L3-L4, L4-L5, and L5-S1, in which lumbar disc hernia occurred frequently, was 7.2%, whereas in L1-L2 it was 10% and 13.3% in L2-L3 level. Higher penetration rates were also found in superior levels in the study of Furman *et al*.

Vasovagal reactions characterized by hypotension, bradycardia, nausea, vomiting, and even loss of consciousness can be expected to be encountered in almost all interventional procedures. Although it is usually benign in nature, it is an undesirable experience for the patients and physicians. Vasovagal reactions defined a subtype of syncope may lead to an interruption of the interventions. The best way to prevent the vasovagal reactions may be a suitable premedication before intervention and performing the intervention under sedation. However, sedation may mask the major complications potentially seen in the intervention being performed. Hence, it was reported that the risk–benefit ratio of giving sedation should be carefully considered while planning an intervention.<sup>30,31</sup> In our study, we observed vasovagal reactions in 8.7% of our patients during or immediately after the intervention, which was the most frequent minor complication that we encountered. The reason for that we accepted it as a minor complication was the observation of mild hypotension without loss of consciousness and nausea without vomiting. Botwin *et al*,<sup>19</sup> in a study evaluating the complications of 322 TLESI performed in 207 patients, reported that only one patient (0.3%) developed vasovagal reaction. In a study about the complications

**TABLE 4. Complications**

|                    | n  | Frequency (%) | Mean Year |
|--------------------|----|---------------|-----------|
| Impotence          | 5  | 1.9%          | 48.8      |
| Vasovagal reaction | 49 | 8.7%          | 39.3      |
| Flushing           | 5  | 0.9%          | 48.6      |

of 306 epidural steroid injections performed in 151 patients via transforaminal in cervical and lumbar levels, Huston *et al*<sup>21</sup> reported that no vasovagal reaction was seen in cervical applications, only one patient (0.5%) developed vasovagal reaction in lumbar application. We think that the implementation of routine sedation is not accurate for neuroaxial interventions that may cause to very hazardous complications for not masking potential complications. For the patients excessively nervous and anxious, sedation should be given by considering risk–benefit ratio. Although there was no information about the sedation in the studies of Botwin *et al* and Huston *et al*, we think that the fact that vasovagal reactions are more commonly encountered in our study is correlated with that we did not give sedation to our patients.

One of the interesting situations that we faced in our study is erectile dysfunction. Erectile dysfunction occurred in five (1.9%) of our 268 men patients is a common male sexual function disorder and its incidence becomes higher by age, although it can be seen in all ages. Erectile dysfunction can be seen with organic reasons (*e.g.*, neurologic, vascular, hormonal defects) as well as without any organic causes (psychological) or mix reasons.<sup>32,33</sup> Although at first, erectile dysfunction may seem like a result of TLESIs application, the fact that the patients with erectile dysfunction are using many different pain medications may be responsible for the etiology. In addition, the fact that our patients were middle aged may create such sensitivity to TLESIs. Therefore, it has to be studied comprehensively to find out if this condition, which was never seen in any previous studies, is really a result of TLESIs.

Flushing occurred in the faces of five patients (0.9%) included in the study after TLESIs. The mechanism of flushing because of steroid administration is unknown; it is presumed that it is resulted from a immunoglobulin (IgE)-mediated mechanism.<sup>34</sup> Varied results about its incidence were reported. Everret *et al* reported the incidence of flushing to be 11% in a study investigating prospectively the incidence of flushing after TLESIs, DeSio *et al*<sup>35</sup> and Botwin *et al*<sup>19,36</sup> reported the incidence of flushing to be 0.9%, 1.2%, and 5.1%, respectively.

One of the severe complications to be occurred in TLESIs interventions is the damage of spinal nerves and dorsal root ganglions.<sup>18,21,27</sup> The puncture of the nerve with a spinal needle with a sharp tip and/or the injection of the agents (such as contrast material, local anesthetics, and steroid) may lead to nerve injury resulted in a disastrous outcome.<sup>37,38</sup> There are some authors proposing alternative TLESIs techniques against to the implementation of TLESIs by traditional subpedicular safe triangle method to prevent this complication. Lee *et al*<sup>39</sup> suggest posterolateral approach, whereas Jeong *et al*<sup>4</sup> suggest preganglionic approach. We routinely use subpedicular safe triangle method in our clinical practice. However, we prefer the nerve stimulator needle with a blunt tip to the spinal needle with pointed and sharp tip for the intervention to minimize the risk of nerve injury. Another reason that we prefer such needles is the presence of a transparent intermediate line. Transparent intermediate line provides either a prediction about vascular penetration and easily injection of the drug at the final step without the risk of displacement of the needle.

Therefore, we think that the use of stimulation needles for the implementation of TLESIs is a more accurate option.

The weakness of our study is the investigation of the complications that belong only to a single technique. But, as mentioned before, there are other techniques for TLESIs apart from subpedicular safe triangle technique. Detailed studies are needed to understand which of them is safer. Further studies may be directed to this point.

## ➤ Key Points

- ❑ Routine sedation should not be given to the patient not to mask the complications that can be faced in TLESIs. If it is necessary, a conscious sedation should be chosen with risk–benefit assessment.
- ❑ Vascular penetration, which is relatively more frequent and potentially hazardous, should be regarded at most. The complications related to vascular penetration can be avoided by a good analysis of the contrast material's distribution.
- ❑ The needles with blunt tip should be used to prevent transient or permanent nerve injury.
- ❑ Transforaminal lumbar epidural steroid applications provide a safe treatment option when it is performed carefully and in expert hands.

## References

1. Verhaak PF, Kerssens JJ, Dekker J, et al. Prevalence of chronic benign pain disorder among adults: a review of the literature. *Pain* 1998;77:231–9.
2. Bressler HB, Keyes WJ, Rochon PA, et al. The prevalence of low back pain in the elderly. A systemic review of the literature. *Spine* 1999;24:1813–9.
3. Stewart WF, Ricci JA, Chee E, et al. Lost productive time and cost due to common pain conditions in the US workforce. *JAMA* 2003;290:2443–54.
4. Jeong HS, Lee JW, Kim SH, et al. Effectiveness of transforaminal epidural steroid injection by using a preganglionic approach: a prospective randomized controlled study. *Radiology* 2007;245(2):584–90.
5. Manchikanti L, Boswell MV. Interventional techniques in ambulatory surgical centers: a look at the new payment system. *Pain Physician* 2007;10:627–50.
6. Friedly J, Chan L, Deyo R. Increases in lumbosacral injections in the Medicare population: 1994 to 2001. *Spine* 2007;32:1754–60.
7. Abdi S, Datta S, Trescot AM, et al. Epidural steroids in the management of chronic spinal pain: a systematic review. *Pain Physician* 2007;10:185–212.
8. Manchikanti L. The growth of interventional pain management in the new millennium: a critical analysis of utilization in the Medicare population. *Pain Phys* 2004;7:465–82.
9. Vad VB, Bhat AL, Lutz GE, et al. Transforaminal epidural steroid injections in lumbosacral radiculopathy. *Spine* 2002;27:11–6.
10. Steward HD, Quinell RC, Dann N. Epidurography in the management of sciatica. *Br J Rheumatol* 1987;26:424–9.
11. White AH, Derby R, Wynne G. Epidural injections for the diagnosis and treatment of low back pain. *Spine* 1980;5:78–86.
12. Holubec J, Holubec D. Evaluation of fluoroscopy in caudal epidural steroid injections. Presented at the North American Spine Society's Eighth Annual Meeting. San Diego, CA: 1993.
13. Mehta M, Salmon N. Extradural block: confirmation of the injection site by radiograph monitoring. *Anesthesia* 1985;40:1009–12.
14. Manchikanti L. Transforaminal lumbar epidural steroid injections. *Pain Phys* 2000;3:374–98.

15. Cluff R, Mehio AK, Cohen SP, et al. The technical aspects of epidural steroid injections: a national survey. *Anesth Analg* 2002;95:403–8.
16. Fenton DS, Czervionke LF. Selective nerve root block. In: Fenton DS, Czervionke LF, eds. *Image-Guided Spine Intervention*. Philadelphia: Saunders; 2003;73–98.
17. Buenaventura RM, Datta S, Abdi S, et al. Systematic review of therapeutic lumbar transforaminal epidural steroid injections. *Pain Phys* 2009;12:233–51.
18. Goodman BS, Posecion LWF, Mallempati S, et al. Complications and pitfalls of lumbar interlaminar and transforaminal epidural injections. *Curr Rev Musculoskelet Med* 2008;1:212–22.
19. Botwin KP, Gruber RD, Bouchlas CG, et al. Complications of fluoroscopically guided transforaminal lumbar epidural injections. *Arch Phys Med Rehabil* 2000;81:1045–50.
20. Stalcupa ST, Crall TS, Giula L, et al. Influence of needle-tip position on the incidence of immediate complications in 2,217 selective lumbar nerve root blocks. *Spine J* 2006;6(2):170–6.
21. Huston CW, Slipman CW, Garvin C. Complications and side effects of cervical and lumbosacral selective nerve root injections. *Arch Phys Med Rehabil* 2005;86:277–83.
22. Goodman BS, Bayazitoglu M, Mallempati S, et al. Dural puncture and subdural injection: a complication of lumbar transforaminal epidural injections. *Pain Phys* 2007;10:697–705.
23. Gilchrist RV, Slipman CW, Bhagia SM. Anatomy of the intervertebral foramen. *Pain Phys* 2002;5:372–8.
24. Bogduk N. *Clinical Anatomy of the Lumbar Spine and Sacrum*. 4th ed. London: Churchill Livingstone, 2005.
25. Lu J, Ebraheim NA, Biyani A, et al. Vulnerability of great medullary artery. *Spine J* 1996;21:1852–5.
26. Houten JK, Errico TJ. Paraplegia after lumbosacral nerve root block: report of three cases. *Spine J* 2002;2:70–5.
27. Glaser SE, Falco F. Paraplegia following a thoracolumbar transforaminal epidural steroid injection. *Pain Phys* 2005;8:309–14.
28. Furman MB, O'Brien ME, Zgleszewski TM. Incidence of intravascular penetration in transforaminal lumbosacral epidural steroid injections. *Spine* 2000;25(20):2628–32.
29. Smuck M, Fuller BJ, Yoder B, et al. Incidence of simultaneous epidural and vascular injection during lumbosacral transforaminal epidural injections. *Spine J* 2007;7:79–82.
30. Chen-Scarabelli C, Scarabelli TM. Neurocardiogenic syncope. *BMJ* 2004;329:336–41.
31. Trentman TL, Rosenfeld DM, Seamans DP, et al. Vasovagal reactions and other complications of cervical vs. lumbar transforaminal epidural steroid injections. *Pain Pract* 2009;9(1):59–64.
32. Tsertsivadze A, Yazdi F, Fink HA, et al. Oral sildenafil citrate (Viagra) for erectile dysfunction: a systematic review and meta-analysis of harms. *Urology* 2009;74(4):831–6.e8.
33. Burls A, Gold L, Clark W. Systematic review of randomised controlled trials of sildenafil (Viagra®) in the treatment of male erectile dysfunction. *Br J Gen Pract* 2001;51(473):1004–12.
34. Everett CR, Baskin MN, Novoseletsky D, et al. Flushing as a side effect following lumbar transforaminal epidural steroid injection. *Pain Phys* 2004;7:427–9.
35. DeSio JM, Kahn CH, Warfield CA. Facial flushing and/or generalized erythema after epidural steroid injection. *Anesth Analg* 1995;80:617–9.
36. Botwin KP, Baskin M, Rao S. Adverse effects of fluoroscopically guided interlaminar thoracic epidural steroid injections. *Am J Phys Med Rehabil* 2006;85:14–23.
37. Fredrickson MJ. Case report: neurological deficit associated with intraneural needle placement without injection. *Can J Anaesth* 2009;56:935–8.
38. Hadzic A, Dilberovic F, Shah S, et al. Combination of intraneural injection and high injection pressure leads to fascicular injury and neurologic deficits in dogs. *Reg Anesth Pain Med* 2004;29(5):417–23.
39. Lee IS, Kim SH, Lee JW, et al. Comparison of the temporary diagnostic relief of transforaminal epidural steroid injection approaches: conventional versus posterolateral technique. *AJNR Am J Neuroradiol* 2007;28(2):204–8.